

A Comprehensive Review of Acne Vulgaris

AK Mohiuddin*

Department of Pharmacy, World University of Bangladesh

Abstract

Acne, also known as Acne Vulgaris (AV), is a long-term skin disease that occurs when hair follicles are clogged with dead skin cells and oil from the skin. It is characterized by blackheads or whiteheads, pimples, oily skin, and possible scarring. An intact stratum corneum and barrier, normal natural moisturizing factor and hyaluronic acid levels, normal Aquaporin-3 (AQP3) expression (localized at the basal lateral membranes of collecting duct cells in the kidney), and balanced sebum secretion are qualities of the skin that fall in the middle of the oily-dry spectrum. Patients rarely, if ever, complain about reduced sebum production, but elevated sebum production, yielding oily skin that can be a precursor to acne, is a common complaint. Several factors are known to influence sebum production. AV is mostly triggered by *Propionibacterium acnes* in adolescence, under the influence of normal circulating Dehydro-Epiandrosterone (DHEA). It is a very common skin disorder which can present with inflammatory and non-inflammatory lesions chiefly on the face but can also occur on the upper arms, trunk, and back. Age, in particular, has a significant and well-known impact, as sebum levels are usually low in childhood, rise in the middle-to-late teen years, and remain stable into the seventh and eighth decades until endogenous androgen synthesis dwindles.

Sebum, the oily secretion of the sebaceous glands containing wax esters, sterol esters, cholesterol, di- and triglycerides, and squalene, imparts an oily quality to the skin and is well known to play an important role in acne development. Acne can't be prevented or cured, but it can be treated effectively. The pimples and bumps heal slowly, and when one begins to go away, others seem to crop up. Depending on its severity, acne can cause emotional distress and scar the skin. Acne may cause scarring of the skin, but generally causes no long-term health problems. In self-body image, some parts of the body including face play an important role. Existence of even a minor lesion in this part may be unpleasant for the patient and seems large. This image can cause mental disorders including depression and anxiety, low self-esteem, and decrease in social relationships. However, high levels of anxiety and depression in patients with facial acne are not related to oxidative stress, according to a study published online in the Journal of Cosmetic Dermatology.

Keywords: Acne, Skin care, Comedones, Pustules, Acne scars, Sebum, *Propionibacterium acnes*.

Abbreviations: Acne Vulgaris (AV); Aquaporin-3 (AQP3); Dehydroepiandrosterone (DHEA); complementary and alternative medicine (CAM); Insulin-Like Growth Factor 1 (IGF-1); Health-Related Quality of Life (HRQoL); Dehydroepiandrosterone (DHEA); Sex Hormone-Binding Globulin (SHBG); Ceramide (Cer); Sphingomyelin (SM); Follicle-Stimulating Hormone (FSH); 5 α -dihydrotestosterone (5 α -DHT); Polycystic ovary syndrome (PCOS); sebaceous gland (SG); eicosapentaenoic acid (EPA); docosahexaenoic acid (DHA); Adult Female Acne (AFA); Benzoyl peroxide (BP); post inflammatory

Article Information

Article Type: Review**Article Number:** JCP103**Received Date:** 28 May, 2019**Accepted Date:** 04 July, 2019**Published Date:** 11 July, 2019

***Corresponding author:** AK Mohiuddin, Assistant Professor, 151/8, Department of Pharmacy, Green Road, Dhanmondi, Dhaka-1205, Bangladesh. Tel: +8801716477485; EMail: [mohiuddin3\(at\)pharmacy.wub.edu.bd](mailto:mohiuddin3(at)pharmacy.wub.edu.bd)

Citation: Mohiuddin Ak (2019) A Comprehensive Review of Acne Vulgaris. J Clin Pharm Vol: 1, Issu: 1 (17-45).

Copyright: © 2019 Mohiuddin Ak. This is an open-access article distributed under the terms of the Creative Commons Attribution License, which permits unrestricted use, distribution, and reproduction in any medium, provided the original author and source are credited.

hyperpigmentation (PIH); American Academy of Dermatology (AAD); methicillin-resistant Staphylococcus aureus (MRSA); combined oral contraceptive (COC); randomized controlled trials (RCTs); Investigator's Global Assessment (IGA); Intense pulsed light (IPL); Non-ablative fractional lasers (NAFL).

Terminology: Whiteheads -closed plugged pores; Blackheads -open plugged pores; Papules-Small red, tender bumps; Pimples-pustules, which are papules with pus at their tips; Nodules-Large, solid, painful lumps beneath the surface of the skin; Cystic Lesions-Painful, pus-filled lumps beneath the surface of the skin; Hirsutism- abnormal growth of hair on a woman's face and body; Alopecia-the partial or complete absence of hair from areas of the body where it normally grows; baldness.

Background

- *Historic Panorama of Acne Protection-* The word 'acne' appears to evolve from Greek word 'acme' which means 'point or spot'. Although acne is described in very ancient writings dating back to Eber's Papyrus, its clear description is found after Fuch's coined the term 'Acne Vulgaris' and Erasmus Wilson separated it from acne rosacea. The roots of acne have been traced all the way to three well known ancient civilizations viz, Egyptians, Greeks and Romans.
- Some Egyptian writings have mentioned that Pharaohs suffered from acne and had also made efforts to resolve it. In Ebers Papyrus the word 'aku-t' is cited that was later translated as 'boils, blains, sores, pustules or any inflammatory swelling' and is described to be treated with some animal origin preparations and honey. Ancient Egyptians around 3rd century was of the opinion that acne is caused by telling lies. Tutankhamun, Egyptian Pharaoh of the 18th dynasty had acne as evident from the anti-acne remedies in his tomb. From the historical records, both Hippocrates and Aristotle were aware of this ailment. Aristotle also explained this condition in detail.
- The ancient Greeks knew acne as 'tovoot'- 'the first growth of the beard' hence it was associated with puberty. Ancient Romans has guided initial treatment of acne.
- In ancient Rome, acne was treated with baths as people there believed that the pores of the skin may be lifted and cleaned with a mixture of sulfur in the mineral baths. Cassius in 3 AD interpreted that since this disorder is related to puberty, it is known by the name of 'akmas'. In the 4th century AD, the court physician of Theodosius advised acne victims to wipe their "pimples" with a cloth while watching a falling star and the pimples would then 'fall from the body'.
- Ibn Sina (980-1037) in his legendary text 'Al Qanoon Fil Tib' (The Cannon of Medicine) has depicted the etiopathogenesis and clinical presentation of Busoore labaniya (acne).
- In the Elizabethan era (1558-1603), the appearance of women was given primordial importance. Acne at that time was also contributed to witchcraft. For the management

of these pimples, different type of mercury makeup was also in use. The caustic mercury erodes the flesh. Hence forth, people restored to the sulfur treatments of antique times.

- Riolanus and Jonston associated acne with disorders of menstruation in 1638 and 1648 respectively. Johnston (1648) also linked acne with heterosexual behavior pattern in a manner very close to present day psychosomatic ideas on the subject.
- In 1920, Jack Breitbart of the Revlon Corporation invented benzoyl peroxide for the treatment of acne which was more effective and smelled better than the sulfur treatments of the past.
- Around 1930, laxatives were in common use for treatment of acne.
- In 1950s Tetracycline was for the first time prescribed for acne as it was noticed that acne was caused by bacteria.
- In 1960s, the topical treatment Retin-A was developed to alleviate acne. Retin-A has produced great results and is still in use.
- In 1980s, a novel medication Accutane (Isotretinoin) for acne appeared in the markets of America. It was found extremely effective but severe side effects were also noted viz., stroke, seizure, heart attack and hair loss.
- In 1990, laser therapy made its evolvment in treating acne and is now widely used remedy as it clears the recent as well as old scars left by acne besides active lesions.
- In 2000, the blue/red therapy was developed along with laser therapy for easy treatment of acne. Micro-needling with derma roller emerged as a novel treatment modality for the treatment of acne scars.
- Fernandes, in 2006, developed percutaneous collagen induction therapy with the derma-roller.
- Vaccine against inflammatory acne has been tested successfully in mice in 2007 and many such studies and trials are detailed in several journals till then.

Introduction

AV is a multifaceted skin disorder, affecting more than 85% of young individuals worldwide. It is the most common skin disease, and although it usually manifests during puberty and worsens throughout adolescence, epidemiological studies suggest that it can arise at any age. Apart from the classic belief that acne results from sebaceous gland hyperplasia, abnormal follicular differentiation with increased keratinization, microbial hyper-colonization of the follicular canal, and increased inflammation primarily through activation of the adaptive immune system may also be contributors. There are various types of acne, such as acne vulgaris, acne rosacea, acne cosmetica, acne fulminans, and acne mechanica. In 2011, around 20% of the population in the US was affected with acne. According to the lesion type, acne can be classified into four main categories: non-inflammatory (purely comedone acne), mild papular, scarring papular, and nodular; the latter three are

inflammatory acne lesions. Acne treatment aims to lessen the inflammatory or non-inflammatory acne lesions, improve appearance, prevent or minimize potential adverse effects, and minimize any scarring. Pharmacological therapy is not always desirable because of the development of antibiotic resistance or the potential risk of adverse effects. Non-pharmacological therapies can be viable alternatives for conventional therapies. Acne severity is classified according to different scales. It is widely agreed, however, that the mild and moderate forms of acne display primary lesions only, while severe acne also includes nodules, cysts, and eventually open lesions. It is noteworthy that acne severity and scarring have been related to *P. acnes* inflammatory factors, bacterial growth metabolites such as allergens, toxins, or porphyrins, and enzymes. Acne is always accompanied by a variety of other signs and symptoms such as erythema, desquamation, burning, itching, dyschromia, and pain.

Furthermore, acne causes significant psychological morbidity in affected patients. Currently available systemic products include the retinoid Isotretinoin, antibiotics, or oral contraceptives, all of which are indicated for more severe acne, acne resistant to other therapies, and nodulocystic, scarring acne. Although acne is widespread with numerous treatment options available, the condition is still not considered curable, prompting further investigation by the pharmaceutical industry. Commonly used treatments aim to reduce the number of inflammatory lesions, inhibit comedones, suppress the growth of *Propionibacterium acne* or reduce sebaceous gland size and secretory activity. People with acne often turn to Complementary and Alternative Medicine (CAM), such as herbal medicine, acupuncture, and dietary modifications, because of their concerns about the adverse effects of conventional medicines. Some researchers have concluded that genetic predisposition and hormonal influences play a more important role in acne than diet. Chinese herbal medicine, manual healing therapies (such as acupuncture and massage), and other traditional and folk remedies may follow similar mechanisms in the treatment of acne. Methodological and reporting quality limitations in the included studies weakened any evidence. All mainstream products can cause severe side effects including, paradoxically, the typical signs and symptoms of acne, and there is therefore a demand for new innovative treatments.

Etiology

The pathogenesis is multifactorial with four primary pathogenic factors including: (a) abnormal hyper-keratinization of the pilosebaceous duct with comedo formation caused by increased androgens; (b) an increase in sebum production from the enlarged sebaceous gland caused by increased androgens; (c) colonization and proliferation of the duct with bacteria, most commonly *P. acnes*, although clear evidence of a causal relationship between *P. acnes* and AV is lacking; and (d) an inflammatory response caused by the immunological activity of *P. acnes* [1]. The adequate control of the four pathogenic mechanisms involved in the appearance of acne lesions is key to treatment success [2-8]. Several exacerbating factors have been suggested including diet, menstruation, sweating, personal stress, ultraviolet

radiation, application of pomades and occupation [9]. Use of medications like lithium, steroids, and anticonvulsants, exposure to excess sunlight, use of occlusive wear like shoulder pads, headbands backpacks, and underwire brassieres, endocrine disorders like polycystic ovarian syndrome and even pregnancy have also reported [10]. The association between diet and acne can no longer be dismissed. Compelling evidence shows that high glycemic load diets may exacerbate acne (also, LGL diet that resulted in the improvement of acne lesions) [11-14]. Food with a high glycemic index is rapidly absorbed, increases serum glucose levels and stimulates increased glucose-dependent insulin signaling [15]. Elevated insulin levels stimulate the secretion of androgens and cause an increased production of sebum, growth of the sebaceous glands and hyper-keratinization, which plays a fundamental role in pathogenesis of AV [11,16-18]. High plasma levels of Insulin-Like Growth Factor 1 (IGF-1) which are caused by consumption of milk, stimulates proliferation of sebocytes, resulting in the development and progression of acne lesions. Skim milk contains less estrogen than whole milk. Estrogen is a hormone that may reduce acne [10,11,20-27]. There is a common medical and lay belief that women experience premenstrual acne flares [28-32]. Summer aggravation of acne reported by 80% patient in a study due to sweating and increased humidity [33]. Acne has also been associated with impaired health-related quality of life (HRQoL), at times with negative impacts as great as that of severe and even life-threatening diseases [34]. However, Zari et al. and Bagatin et al. [35,36] revealed positive association with menstruation, heat and humidity, sweating, use of makeup and cosmetic products, oily hair products, use of topical steroids, sleep disorders, excessive skin washing, possible resistance to *P. acnes* and squeezing pimples. Bondade et al. [37] found undesirable stressful life events and psychiatric comorbidity were more in acne patients than in controls. Stress and depression positively correlate with acne severity [35,38]. Acne can also develop in neonates but in most cases resolves spontaneously [39]. Acne neonatorum, which presents within the first four weeks of life, occurs in up to 20% of newborns. Additionally, childhood acne is strongly correlated with the development of persistent acne later in life (Table 1).

Epidemiology

Acne is a very common skin disease with the prevalence among adolescent is 80% or more [15,30,56-61]. Among them 80% are teenagers [62-65]. Although this inquisitive nature is considered a normal aspect of the maturation process, approximately 80% to 90% of teenagers in the Western world experience behavioral/emotional and physical/psychological effects caused by acne [66]. About 60% of affected adolescents have mild acne for which they use non-prescription preparations without consulting a physician. The remaining 40% constitute the population of acne patients seen in medical practice [5]. It is less common in African-Americans and Asians than in the Caucasian population [11]. About 20% of the affected individuals develop severe acne which results in scarring [27]. In youths, overweight and obesity are inversely associated with acne in a dose-dependent manner [67]. Overweight and obesity are

Table 1: Sebaceous Gland and Acne [40-55].

<ul style="list-style-type: none"> • The sebaceous gland (SG) is integral to the structure and function of the skin, providing 90% of its surface lipids. While much of the focus relating to the sebaceous gland comes from its central role in AV. • If sebum interferes with the process of follicular keratinization in the pilosebaceous unit, pore blockage may occur, contributing to lesion formation and acne. • Low levels of linoleic acid have been observed in skin surface lipids of acne patients. Depletion of linoleic acid in sphingolipids has been hypothesized to be involved in the follicular hyperkeratosis, which is a crucial event involved in the comedones formation. After 10 weeks of omega-3 fatty acid or γ-linoleic acid supplementation, inflammatory and non-inflammatory acne lesions decreased significantly. • Typical western diet, comprised of milk and hyper-glycaemic foods, may have potentiating effects on serum insulin and insulin-like growth factor-I (IGF-I) levels. Several studies have shown that elevated levels of serum IGF-I correlate with overproduction of sebum and acne. Also, there is a relationship between female acne and Insulin Resistance (IR). This association is independent of hyperandrogenemia. Anti-insulin drugs may be an adjunctive treatment of female acne. • Another hallmark of sebum in acne patients is the presence of lipoperoxides, mainly due to the peroxidation of squalene and a decrease in the level of vitamin E, the major sebum antioxidant. • The researchers found that the levels of serum vitamins A and E and zinc were significantly lower in the people with acne. • When sebocytes were incubated with an H-1 receptor antagonist, Diphenhydramine (DPH), at non-cytotoxic doses, a significant decrease in squalene levels, a biomarker for sebum, was observed. Acne sebum presents a higher level of squalene peroxide. • Retinoids are also suggested to influence the biological function of sebocytes. Retinoic acid receptors and retinoid X receptors are expressed in human sebocytes. • Acne patients produced higher rates of testosterone and 5α-Dihydrotestosterone (5α-DHT) in their skin than healthy individuals. • Androgens are important hormones that influence sebum production from the sebaceous glands. Highest density of these has been demonstrated in sebaceous glands. Androgens are not directly correlated with acne severity, but affect acne severity as seen in difference between their levels in different grades of acne. • Dehydroepiandrosterone (DHEA) has been also shown to regulate sebum production especially in postmenopausal women. • In AV, increased sebum production peaks in mid-adolescence at a time that GH and IGF-I reach their highest serum levels. • At puberty, sebum production is increased by the multiple factors including androgens, corticotropin-releasing hormone, vitamin D and insulin-like growth factor-1 (IGF-1). • In acne-involved skin the complete CRH system [Neuropeptides (NPs)] is abundant especially in the sebaceous glands. • Inflammation is being regarded as a key component of the pathogenesis of acne. The main factors associated with acneiform lesion development are follicular hyperkeratinization, sebum production by sebaceous glands, and inflammation. • Cytokines are present in normal sebaceous glands, and they are affected by many factors. In a stressed environment, the amounts of released cytokines increase significantly. • The sebum excretion rate exerts a profound influence on the rate of growth of <i>P. acnes</i> and may determine, along with availability of water, whether a particular follicle is capable of being colonized. Certain <i>P. acnes</i> strains to be responsible for opportunistic infections worsening acne lesions.

associated with acne in girls aged 18 and 19, but the same association was not observed in boys [68]. However, Stewart et al. [69] found no significant association between increased BMI and AV. Western nutrition is characterized by high calorie uptake, high glycemic load, high fat and meat intake, as well as increased consumption of insulin- and IGF-1-level elevating dairy proteins. Intake of instant noodles, junk food, carbonated drinks, snacks, processed cheeses, pork, chicken, nuts and seaweed were significantly higher in acne patients than in the controls. Moreover, positive associations between acne and the consumption of other dairy products like instant breakfast drink, sherbet, cream cheese and cottage cheese have been reported [70]. Wang et al. [71] reviewed that a nearly 50% of normal women with acne did not have clinical or biochemical evidence of hyperandrogenism. More than 60% of women had an increase in the number of inflammatory acne lesions in the late luteal phase of the menstrual cycle [28-32]. Acne is common during pregnancy. In fact, more than one out of every two pregnant women can expect to develop acne [72]. Girls must be made aware that cosmetic usage may be a potential aggravating factor for their facial acne [73]. Because certain chemicals in personal

care products are suspected endocrine disruptors (e.g. phthalates, parabens, triclosan) [74]. There are many causes for acneiform eruptions including exposure to halogenated aromatic hydrocarbons and use of antibiotics like macrolides and penicillin. Other drugs that can also induce acneiform eruptions include nystatin, isoniazid, corticotropin, naproxen, and hydroxychloroquine. Many organisms can also induce acneiform eruptions like infections by *Proteus*, *Klebsiella*, *Escherichia coli*, and *Enterobacter*. Pityrosporum folliculitis caused by *Malassezia furfur* may also present on the trunk and upper extremities with pruritic eruptions [75]. Black individuals are more prone to post-inflammatory hyperpigmentation and specific subtypes such as 'pomade acne'. The heritability of acne is almost 80% in first-degree relatives [76]. George et al, 2018 revealed Food items and cosmetics were attributed to exacerbation by 47.3% and 40% of patients respectively. About 48% patients had first degree relatives with present or past history of acne [77]. Daily soft drink consumption significantly increases the risk of moderate-to-severe acne in adolescents, especially when the sugar intake from any type of soft drink exceeds 100 g per day [78] (Table 2).

Table 2: Acne Myths/Misconception Vs Study Result.

Myth/Misconception	Study Result
In particular, no effect has been established between chocolate, dairy products, shellfish, or fatty foods [79].	Dark chocolate consumption appears to affect the facial skin of young men by enhancing corneocyte desquamation and promoting bacterial colonization of the residual skin surface components [80].
	Any dairy, such as milk, yogurt, and cheese, was associated with an increased OR for acne in individuals aged 7–30 years [22].
	Four ounces of shrimp provides about 325 -375 milligrams of omega-3 fatty acids [81]. After 10 weeks of omega-3 fatty acid supplementation, inflammatory and non-inflammatory acne lesions decreased significantly [45].
	Isotretinoin, Retinol (Vitamin A), carotenoids (provitamin A) and retinoids (Vitamin A metabolites) are absorbed better with parallel intake of vegetable oils [13].
Weight loss and the use of metformin are both associated with lower plasma insulin levels and decreased androgen levels and therefore for acne patients, a weight loss diet may be indicated [82,83].	Low glycemic loads, with or without metformin, has been associated with greater reduction in acne lesion counts compared with high loads [71].
There were no significant correlations between IGF-1 and acne severity [83].	Plasma IGF-1 levels positively correlate with severity of acne [20].
Too much sex or masturbation may worsen acne. when females begin having a regular sex life their acne will be improved [79], [84]. Masturbation results in general debility, unnatural pale eyes and forehead acne [85].	Despite popular myth, diet, lack of exercise, lack of hygiene, greasy hair hanging over the face, and masturbation do not have any effect [86]. After adjustment for sex and age, the presence of acne remained highly associated with less sexual activity [87].
open comedones or blackheads are full of dirt [88].	The dark color of blackheads has nothing to do with dirt: They look dark because this kind of blackhead is “open” and the skin pigment melanin reacts with oxygen in the air [89].
One should pop pimples at first sight.	Although squeezing pimples may make skin look better in the short term, it might force the pus even deeper into skin, which can make it become even more inflamed and the chance that the area will become dark as it tries to heal [89].
Sitting in the Sun to Clear Pimples	AV is aggravated by sunlight. Acne solaris a form of acne that appears and relapses after sun exposure. However, clinicians should not be didactic in their recommendations regarding diet, hygiene and face-washing, and sunlight to patients with acne. Advice should be individualized [90-92].

Pathophysiology

Acne is proposed to be an IGF-1-mediated disease, modified by diets and smoking increasing insulin/IGF1-signalling [93]. The main hormones responsible for the development of AV include androgens, insulin and insulin-like growth factor-1. Other factors involved in this process are corticotrophin-releasing hormone, α -melanocyte-stimulating hormone and substance P [94]. During puberty, alteration of the sebaceous lipid profile, called dysmenorrhea, stress, irritation, cosmetics and potential dietary factors lead to inflammation and formation of different types of acne lesions [95,96]. Distended follicles rupture and release pro-inflammatory chemicals into the dermis, stimulating inflammation. *P. acnes*, *Staphylococcus epidermis*, and *Malassezia furfur* induce inflammation and induce follicular epidermal proliferation [96]. Androgens also affect the barrier function of the skin, and disturbances of barrier function may stimulate epidermal DNA synthesis. This leads to epidermal hyperplasia, which may also contribute to follicular hyperkeratosis in acne [97]. Foam cells are lipid-loaded macrophages and neutrophils that are generated from a massive uptake of oxidized lipid. Foam cells are a pathological hallmark of atherosclerosis, and have also been found in acne lesions [98]. Sphingolipids are a class of lipids composed of a backbone of spingoid bases that are modified to produce ceramide (Cer) and more complex compounds, such as Sphingomyelin (SM) and glycosphingolipids [99], have both structural and biological

functions in human epidermis. Ceramide is the central molecule in the sphingolipid pathway [100]. They are among the most important epidermal sphingolipids and compose about 50 % of intercellular stratum corneum lipids by mass and are involved in the prevention of trans-epidermal water loss [101]. Kaya et.al, 2019 reported AV patients had increased circulating levels of C16 SM, Ceramide-1-Phosphate (C1P) and lower circulating levels of C24 CER compared to healthy controls, which may provide prognostic value for the disease [102]. Sebum is particularly abundant at anatomic sites with high concentration of *P. acnes*, and the sebum component oleic acid has been reported to promote growth of *P. acnes* in culture. Increased sebum production and follicular hyperkeratosis result in the development of micro comedones, and changes in follicular milieu in intensive growth of *P. acnes*. With proliferation, *P. acnes* secretes various several pro-inflammatory products. These include lipases, proteases, hyaluronidases, and chemotactic factors. Immune response to *P. acnes* includes humoral and cell-mediated immunity as well as complement activation (Figure 1) [103,104].

Economic Burden of AV

The economic burden of acne is substantial. This disorder is generally considered mild but represents a high economical and psychological burden for the society. Approximately 50 million individuals within the United States are affected by acne, making it one of the most common dermatological complaints in patients presenting to a general dermatology

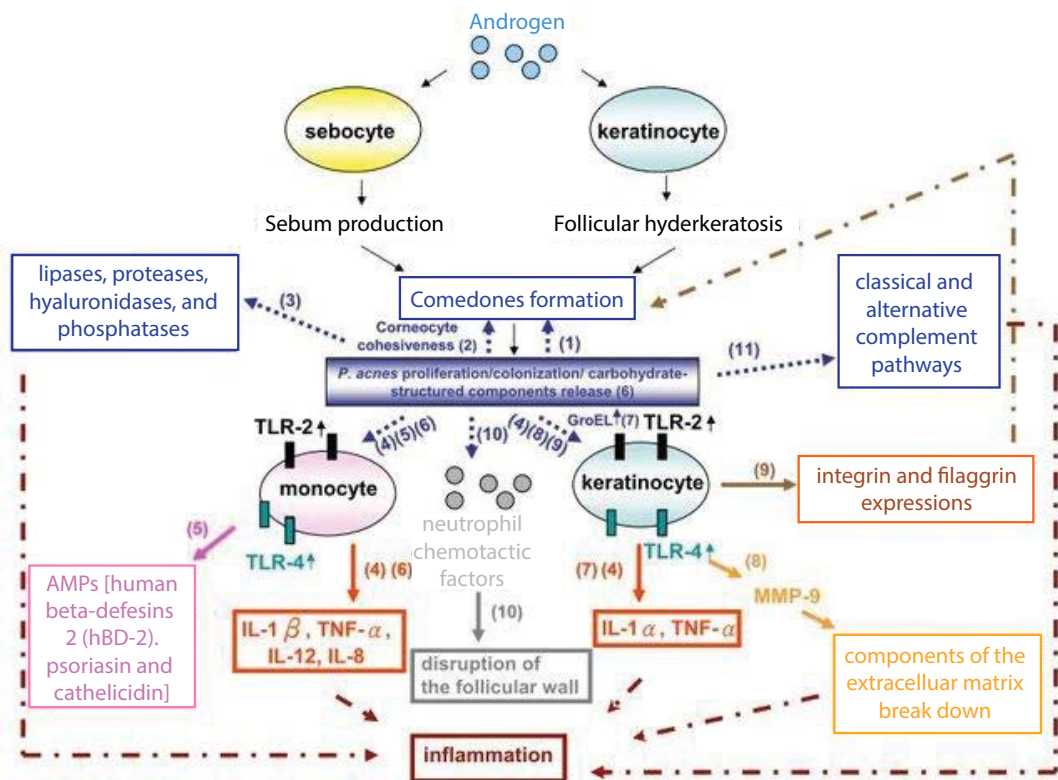


Figure 1: Molecular mechanisms by which *P. acnes* may contribute to the pathogenesis of AV [74]. (1) *P. acnes* is involved in the formation of microcomedones. (2) *P. acnes* colonization leads to an increase in the cohesiveness of corneocytes during the formation of comedones; (3) in vitro studies have suggested that *P. acnes* produces lipases, proteases, hyaluronidases, and phosphatases that may cause tissue injury; (4) *P. acnes* induces the expression of the proinflammatory cytokines IL-8, IL-12, IL-1 α , IL-1 β , and tumor necrosis factor alpha by innate cells, such as keratinocytes and monocytes, through the TLR2-dependent pathway; (5) host cells have developed a protective antimicrobial response to *P. acnes* such as antimicrobial lipids, AMPs (human beta-defensin 2, psoriasin and cathelicidin), exhibiting synergistic activities and inducing proinflammatory cytokines/ chemokines via TLR4- and CD14-dependent mechanisms; (6) the peptidoglycan-polysaccharide complexes and lipoteichoic acids of *P. acnes* stimulate proinflammatory cytokines released from monocytes, demonstrating their high antigenicity in severe acne patients. Increased expression of TLR2 and TLR4 in vivo was found in the epidermal layers of acne lesions for the sensing of peptidoglycans and lipopolysaccharides (LPSs), respectively; (7) *P. acnes* induces the growth of keratinocytes in vitro and upregulates the production of proinflammatory cytokines via a heat-shock GroEL protein; (8) MMPs, produced by different types of cells, including keratinocytes and sebocytes, play important roles in acne inflammation, dermal matrix destruction and hyperproliferative skin disorders. MMPs also cause rupture of the pilosebaceous follicle to exacerbate inflammation. For example, *P. acnes* induces the expression of MMP-9 in keratinocytes for the inflammatory process; (9) *P. acnes* lysates can directly modulate the differentiation of keratinocytes by inducing the expression of b1, a3, a6s, and aVb6 integrins and filaggrin during the formation of comedones; (10) *P. acnes* produces additional neutrophil chemotactic factors and is ingested by neutrophils within the sebaceous follicle, resulting in the release of hydrolases from neutrophils to disrupt the follicular wall; and (11) *P. acnes* results in the formation of C5a in inflammatory acne lesions by activating both the classical and alternative complement pathways.

office [105]. Patients experience high levels of anxiety, depression, and low self-esteem which leads to impaired quality of life. Therefore, treatment should focus on early intervention to decrease the physical and esthetic burden of the disease, and improvement of quality of life [106]. The cost is estimated to exceed \$1 billion per year in USA for direct acne therapy, with \$100 million spent on various acne products, as stated by Changqiang et.al. [107]. According to Bhate et al. [108] it was over 3 billion dollars per year in terms of treatment and loss of productivity. With the rapid economic growth and concomitant changes of lifestyle in China, the demand for facial beauty has been surprisingly increased. In the general esthetic pursuit of fairer skin in East Asia, Chinese people increasingly pay attention to post-acne outcomes such as scars and PIH, in addition to the disease per se [109]. Zhang et al. [110] revealed that higher brand-name usage and a broader range of topical steroids prescribed by specialists than primary care, which were associated with increased costs. The most common drug class utilized was

topical antibiotics, accounting for 63% of all prescriptions. Acne affects a large proportion of the Canadian population and has psychosocial and financial consequences. A 2016 study shows Oral Isotretinoin 3-month costs ranged from \$400 to \$500 (approx.) [111]. Many methods have been performed to achieve a satisfying outcome in acne scars but some of them were high cost and also were associated with low results and some complications [112].

Clinical Diagnosis

The diagnosis of AV is primarily clinical. The common differential diagnosis of acne includes folliculitis, keratosis pilaris, perioral dermatitis, seborrheic dermatitis and rosacea. History and physical examination can help determine if there is an underlying cause of the acne, such as an exacerbating medication or endocrinologic abnormality causing hyperandrogenism (e.g., polycystic ovarian syndrome). Other dermatologic manifestations of androgen excess include seborrhea, hirsutism and androgenetic

alopecia. Endocrinologic testing is not ordered routinely for women with regular menstrual cycles. Older women, especially those with new-onset acne and other signs of androgen excess (e.g., hirsutism, androgenic alopecia, menstrual irregularities, infertility), should be tested for androgen excess with measurements of total and free serum testosterone, dehydro-epiandrosterone, and luteinizing and follicle-stimulating hormone levels. Pelvic ultrasonography may show the presence of polycystic ovaries. In pre-pubertal children with acne, signs of hyperandrogenism include early-onset accelerated growth, pubic or axillary hair, body odor, genital maturation and advanced bone age [113] (Tables 3-5).

Acne Scars

Acne affects the face in a majority of cases, with many patients experiencing some degree of scarring, the severity of which correlates to acne grade. Acne scars result from an altered wound healing response to cutaneous inflammation, with inflammatory cell infiltrates found in nearly 80% of atrophic scars. Almost all scars (99%) originate from papules and pustules (inflammatory lesions) and post-inflammatory lesions [127]. Different P. acnes phylotypes differentially activate epidermal innate immunity, contributing to variations in acne severity. In patients not prone to scarring, early lesions have a large, nonspecific immune response that

Table 3: Grading severity of acne [27,113,89].

Grade	Severity	Clinical findings
I	Mild	Open and closed comedones (blackheads or whiteheads) with few inflammatory papules and pustules. Open comedones are due to plugging of the pilosebaceous orifice by sebum on the skin surface. Closed comedones are due to keratin and sebum plugging the pilosebaceous orifice below the skin surface. The more oil builds up, the more likely it is that bacteria will multiply and lead to inflammatory acne. Acne is also considered to be "mild acne" if someone only has a few pimples, or only has small ones.
II	Moderate	Inflammatory lesions present as a small papule with erythema. Inflamed pimples are called "papules" (small bumps) or "pustules" (filled with yellow pus), mainly on face.
III	Moderately severe	Numerous papules and pustules, and occasional inflamed nodules, also on chest and back
IV	Severe	People who have severe forms of acne have a lot of papules and pustules, as well as nodules on their skin. These nodules are often reddish and painful. The acne may lead to scarring.

Table 4: Clinical Diagnosis of Acne [115-126].

Diagnosis	Differentiating characteristics
Bacterial folliculitis	Abrupt eruption; spreads with scratching or shaving; variable distribution. Because both AV and folliculitis can present as inflammatory erythematous papules, pustules or nodules, they are often hard to distinguish.
Acne keloidalis nuchae	Often seen in black patients; lesions localized to the posterior neck; initially papules and pustules that may progress to confluent keloids
Acneiform eruptions	Secondary to systemic medications, topical corticosteroid medications, contrast dye, and cosmetic products; may be abrupt in onset and correlation with exposure; improvement with cessation of exposure.
Chloracne	Comedones, pustules, and cysts that localize to the post-auricular area, axillae, and groin; history of exposure to halogenated aromatic hydrocarbons; patient may have other systemic manifestations
Favre-Racouchot	Open and closed comedones on periorbital and malar areas; no inflammatory lesions; patients are usually older with a history of significant sun exposure
Periorificial dermatitis	Papules and pustules in the periorificial distribution; often exacerbated by topical corticosteroid use
Pyoderma faciale	Rapid onset of erythema, abscesses, cysts, and possible sinus tracts, no comedones
Syringoma	Noninflammatory papules that typically localize to the eyelids and malar cheeks; skin biopsy test results show dilated cysts with tadpole appearance
Drug-induced acne	There are many causes for acneiform eruptions including exposure to halogenated aromatic hydrocarbons and use of antibiotics like macrolides and penicillin. Other drugs that can also induce acneiform eruptions include nystatin, isoniazid, corticotropin, naproxen, hydroxychloroquine, cyclosporin A, antimycotics, gold salts, isotretinoin, clofazimine, epidermal growth factor receptor inhibitors (cetuximab, gefitinib, and erlotinib), and interferon-beta.
Hidradenitis suppurativa (HS), also called acne inversus.	Double comedo; starts as a painful boil; sinus tracts. A nearly 40% of individuals with HS report an affected first-degree relative, suggesting a hereditary component with an autosomal dominant transmission pattern. It is a chronic inflammatory skin condition with lesions including deep-seated nodules and abscesses, draining tracts, and fibrotic scars. These lesions most commonly occur in intertriginous areas and areas rich in apocrine glands. Among the most common are axillary, groin, perianal, perineal, and inframammary locations.
Miliaria	"Heat rash" in response to exertion or heat exposure; non-follicular papules, pustules, and vesicles. Miliaria is a clinical diagnosis. Laboratory tests are often inconclusive and not helpful. Dermoscopy has been found to be a useful tool, particularly in people with darker skin, revealing large white globules with surrounding darker halos (white bullseye). When in doubt, a skin punch biopsy would be useful to help with diagnosis.
Perioral dermatitis	Papules and pustules confined to the chin and nasolabial folds; clear zone around the vermilion border.
Adenoma sebaceum	Small waxy papules over the medial cheeks, nose, and forehead; multiple lesions associated with tuberous sclerosis; skin biopsy test results show dermal fibrosis and vascular proliferation and dilatation (angiofibromas). Facial angiofibromas are also a feature of multiple endocrine neoplasia type I and, rarely, Birt-Hogg-Dubé syndrome.
Pseudofolliculitis barbae	Affects curly-haired persons who regularly shave closely, with a high prevalence in men of subequatorial African ancestry and, to a much lesser extent, Indo-Europeans. But it can affect both men and women of all ethnicities. Invariably reported as being associated with shaving, also evidence suggests a strong genetic component in patients with persistent PFB.

Diagnosis	Differentiating characteristics
Rosacea	Erythema and telangiectasias; no comedones. Rosacea can also involve the eyes and even a bulbous nose. Acne is seen most commonly in teens, while rosacea occurs most often much later. Also, unlike in patients with rosacea, blackheads are generally present, and bumps and pimples on the trunk and arms are common.
Seborrheic dermatitis	Greasy scales and yellow-red coalescing macules or papules. Seborrheic dermatitis presents as ill-defined erythematous patches with greasy scale distributed on the eyebrows, glabella, paranasal skin, nasolabial folds, beard, scalp, and chest. Azelaic acid may be especially valuable in this application because of its efficacy in treating concomitant rosacea and acne.

Table 5: Laboratory tests in patients with suspected hormonal acne [30].

Testosterone	Minimal to modest elevations of <200 ng/dL are suggestive of a benign cause of ovarian or adrenal cause while above this level; neoplasia of ovarian or adrenal origin should be suspected.
Androstenedione	Secreted equally by ovaries and adrenals and follows a circadian rhythm making early morning samples, the best to analyze.
DHEA	High levels of DHEA >8,000 ng/dL and dehydroepiandrosterone sulfate (DHEAS) should raise concern of adrenal tumors, while levels of DHEAS (4,000–8,000 ng/dL) indicate benign adrenal hyperplasia.
SHBG	Decreased levels of SHBG lead to free unbound testosterone in excess, resulting in more manifested signs.
Prolactin	Elevated prolactin could point out to hypothalamic or pituitary causes for further assessment and investigation.
17-Hydroxy progesterone	Elevated (>200 ng/dl) in congenital adrenal hyperplasia or non-classic congenital adrenal hyperplasia due to deficiency or absence of 21 α -hydroxylase.
Luteinizing hormone	Follicle-stimulating hormone (FSH) ratio: a ratio of >2 is indicative of possible PCOS.
Fasting and postprandial insulin	Overweight and obese patients should be checked for insulin levels.
Serum cortisol	High levels are an indication of adrenal neoplasia.

subsides in resolving lesions. In contrast, in patients prone to scarring, early lesions are characterized by a smaller number of skin-homing CD4+ T-cells compared to non-scarring patients, a response that becomes more active in resolving lesions [128]. Studies report the incidence of acne scarring in the general population to be 1 to 11%. Having acne scars can be emotionally and psychologically distressing to patients. Rather than fading with time, the appearance of scars often worsens with normal aging or photo damage [129] (Figure 2) (Table 6).

Psychological Impact of AV

Along with acne, having acne scars is a risk factor for suicide and also may be linked to poor self-esteem, depression, anxiety, altered social interactions, body image alterations, embarrassment, anger, lowered academic performance, and unemployment [129]. Studies have also shown that the psychological impact of acne appears to affect more females than males [36]. Facial appearance has an important role in self-perception, as well as in the

interaction with others; face lesions cause a significant impact in women's quality of life [134]. The psychological impact of acne is generally significant and largely underestimated; stress during professional and private life, anxiety and sleep quality, in particular, have a reciprocal relationship with disease susceptibility and severity [135]. Suicidal ideation was found in 6-7% of acne patients. Psychological issues such as social dysfunction such as reduced/avoidance of social interactions with peers and opposite gender also reported. Acne can negatively influence the intention to participate in sports [136]. Psychiatric symptoms such as somatization, obsession, sensitivity, hostility, phobia, paranoid ideation, and psychoticism were associated with this skin disorder [137]. The degree of impairment in QOL significantly increased with increase of clinical severity of acne, with presence of post acne hyper pigmentation and scarring. In a study in Middle East, 23% of acne female students reported that they had difficulty in sports because of acne; while, a study among Scottish students found that 10% of acne sufferers avoided swimming and other

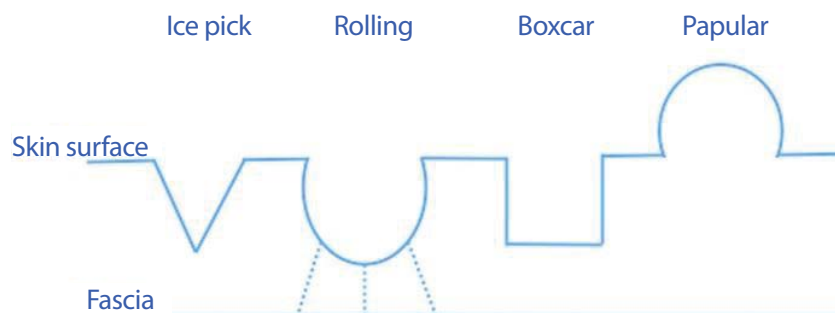


Figure 2: Acne Scar Types [139]. Ice pick scars are narrow, deep, and extend vertically to the deep dermis or subcutaneous tissue. Rolling scars occur from fibrous anchoring of the dermis to the subcutis, leading to superficial shadowing and an undulating appearance to the overlying skin. Boxcar scars are round-to-oval depressions with sharply demarcated vertical edges. Papular scars, unlike the depressed morphology of ice pick, rolling, and boxcar scars, are exophytic in nature and produce a cobblestone-like appearance.

Table 6: Acne Effects [89,129-133].

Atrophic scars	Atrophic acne scarring is an unfortunate, permanent complication of AV, which may be associated with significant psychological distress. It is most likely related to inflammatory mediators and enzymatic degradation of collagen fibers and subcutaneous fat. The most basic, practical, system divides atrophic acne scars into the following three main types: a) icepick, b) rolling, and c) boxcar scars
(a) Icepick	Icepick scars are narrow (<2 mm), deep, sharply margined epithelial tracts that extend vertically to the deep dermis or subcutaneous tissue.
(b) Rolling	Rolling scars occur from dermal tethering of otherwise relatively normal-appearing skin and are usually wider than 4 to 5 mm. Abnormal fibrous anchoring of the dermis to the sub-cutis leads to superficial shadowing and a rolling or undulating appearance to the overlying skin.
(c) Boxcar	Boxcar scars are round to oval depressions with sharply demarcated vertical edges, similar to varicella scars. They are clinically wider at the surface than icepick scars and do not taper to a point at the base.
Hypertrophic scars	These raised scars can form on chest, back or shoulders, particularly in people who have severe acne. They develop if too much connective tissue is produced while the wound is healing. This type of acne scar is less common.
Papular Scars	Papular scars can clinically mimic closed comedones, acne, and granulomas, leading to an unnecessary delay in appropriate treatment. Active acneiform lesions causing any type of scars should be treated aggressively with systemic therapy to prevent further progression of scarring. Papular scars are 3 to 4mm skin-colored cobblestone-like papules distributed anywhere on the body but, in our clinical experience, most commonly on the chin, nose, and back. Also known as white papular acne scars, these flesh-colored papules are often incorrectly diagnosed as acne and do not respond to traditional acne treatments.
Keloid Scars	Keloids result from abnormal wound healing in response to skin trauma or inflammation. Keloid development rests on genetic and environmental factors. Higher incidences are seen in darker skinned individuals of African, Asian, and Hispanic descent. Keloid scars also form when too much connective tissue is made. Unlike hypertrophic scars, though, they are bigger than the original inflamed area. This is a very rare type of acne scarring. In keloids, the fibroblastic phase continues, unchecked, resulting in the clinical and histopathological findings.

sports because of embarrassment [138]. The management of adult female acne should encompass not just medical treatment of the symptoms, but also a comprehensive, holistic approach to the patient as a whole, her individual lifestyle factors and the impact of acne on her quality of life [135]. Compared with heterosexuals, sexual minorities report higher rates of depression, suicidal ideation, and body image issues. Consequentially, sexual minorities with acne may be a group at high risk for development of mental health problems [139]. Sexual distress was particularly higher in female than in male patients with Acne Inversa. Surprisingly, severity of cutaneous alterations correlated neither with sexual dysfunctions nor with sexual distress [140]. The relationship between isotretinoin and depression is the most debated aspect of isotretinoin therapy [141]. It is prudent for the practitioner to continue to use isotretinoin to treat severe acne, while at the same time informing patients and their relatives that depressive symptoms should be actively assessed at each visit and, if necessary, referral to a psychiatrist and a discontinuation of isotretinoin should be considered [142].

Acne Management

In recent years, due to better understanding of the pathogenesis of acne, new therapeutic modalities and various permutation and combinations have been designed. In topical agents; benzoyl peroxide, antibiotics, retinoids, etc., are the mainstay of treatment; can be given in combinations. While systemic therapy includes oral antibiotics, hormonal therapy, and isotretinoin, depending upon the need of patients it has to be selected. Physical treatment in the form of lesion removal, photo-therapy is also helpful in few of them. Due to convenience, lower cost, and difficulty getting an appointment with a dermatologist, the use of over-the-counter acne treatments is on the rise. Commonly referred to as "cosmeceuticals," OTC acne treatments come in lotions,

creams, washes, kits, scrubs, brushes, and devices. Due to the sheer number of different OTC brands, plus newer products constantly being developed, it is hard for both physicians and patients to keep abreast of the numerous products. However, all treatments for AV are theoretically designed to target one or more of the pathogenic pathways involved in the development of AV lesions. In moderate acne, combination therapy has shown the most favorable results and typically consists of a regimen including benzoyl peroxide, topical antibiotics, and a topical retinoid (tretinoin, adapalene, or tazarotene). Tretinoin, adapalene, and tazarotene demonstrate similar effectiveness in the reduction of inflammatory, non-inflammatory, and total lesion counts after 12 weeks of treatment. Oral antibiotics may be tried for patients with a predominance of inflammatory lesions who have not responded favorably to the above topical treatments (Table 7).

Acne prevention

The relationship between diet and acne is highly controversial. Several studies during the last decade have led dermatologists to reflect on a potential link between diet and acne. Selected dietary factors on the course of AV are milk and dairy products, chocolate, glycemic load of the diet, dietary fiber, fatty acids, antioxidants, zinc, vitamin A and iodine.

A. Milk and dairy products: High intakes (≥ 2 glasses per day) of full-fat dairy products were associated with moderate to severe acne. No significant associations were found between acne and intake of semi-skimmed or skimmed dairy products, and not with moderate intakes of any fat variety of dairy products [144]. Also, no significant association between yogurt/cheese and acne development was observed by Aghasi et al. [145]. However, a person can reduce or prevent acne breakouts by consuming fewer dairy products, and fewer foods with

Table 7: Different treatment options for acne [143].

Treatment Methods	Examples
Topical	Retinoids: adapalene, isotretinoin, tretinoin, tazarotene, tretinoin
	Antibiotics: clindamycin, erythromycin
	Diverse: azelaic acid, benzoyl peroxide, chemical peels, corticosteroids, dapsone, hydrogen peroxide, niacinamide, salicylic acid, sodium sulfacetamide, sulfur, triclosan
Systemic	Retinoids: isotretinoin
	Antibiotics: azithromycin, clindamycin, co-trimoxazole, doxycycline, erythromycin, levofloxacin, lymecycline, minocycline, roxithromycin
	Hormonal: contraceptives
Complementary and Alternative Medicines (CAM)	Diverse: clofazimine, corticosteroids, ibuprofen, zinc sulfate
	<i>Achillea millefolium</i> , amaranth, antimicrobial peptides, arnica, asparagus, basil oil, bay, benzoin, birch, bittersweet nightshade, black cumin, black walnut, borage, Brewer's yeast, burdock root, calendula, celandine, chamomile, chaste tree, <i>Commiphora mukul</i> , copaiba oil, coriander, cucumber, duckweed, Du Zhong extract, English walnut, <i>Eucalyptus dives</i> , fresh lemon, garlic, geranium, grapefruit seeds, green tea, jojoba oil, juniper twig, labrador tea, lemon grass, lemon, minerals, neem, oak bark, onion, orange peel, orange, Oregon grape root, patchouli, pea, petitgrain, pine, pomegranate rind extract, poplar, probiotics, pumpkin, resveratrol, rose myrtle, rhubarb, <i>Rosa damascena</i> , rosemary, rue, safflower oil, sandalwood, seaweed, soapwort, <i>Sophora flavescens</i> , specific antibodies, stinging nettle, sunflower oil, <i>Taraxacum officinale</i> , taurine bromamine, tea tree oil, thyme, turmeric, vinegar, vitex, witch hazel, <i>Withania somnifera</i> and yerba mate extract
Physical Treatment	Comedone extraction, cryoslush therapy, cryotherapy, electrocauterization, intralesional corticosteroids and optical treatments

a high glycemic index. Acne that occurs after ingestion of foods rich in iodine appears suddenly and is characterized by many papules. The association between acne and milk may also be a result of the iodine content of milk [11].

B. Chocolate Restriction: Chocolate consumption primed human blood mononuclear cells to release more proinflammatory cytokines, interleukin-1 β , and TNF α , upon stimulation with *Propionibacterium acnes*. Because over-inflammation is an important contributor to acne pathogenesis and the anti-inflammatory dose effect of antibiotics has been demonstrated to be most effective in treating acne, it is plausible that altered cytokine profiles can contribute to worsening acne [146]. Dark chocolate contains more antioxidants than milk chocolate, which would lead to conclusion that it may have much smaller comedogenic effects [11]. Some say that avoiding things like meat, milk or chocolate improved their complexion.

C. Glycemic Load: The improvement in acne and insulin sensitivity after a low-glycemic-load diet suggests that nutrition-related lifestyle factors may play a role in the pathogenesis of acne [147]. A high glycemic index (GI) and glycemic load (GL) diet may stimulate acne proliferative pathways by influencing biochemical factors associated with acne. A low GI and GL diet decreased IGF-1 concentrations, a well-established factor in acne pathogenesis [148]. Having fast food like fries/chips and soda can dramatically increase the calories, carbohydrate, fat, and GL of the nutritionally promoted fast-food meal [149]. Cordain et al. suggested that a low-fat intake and low glycemic load diet may be the cause of acne absence in both populations [150]. Processed foods, especially those with a high glycemic index, have been known to exacerbate acne. One study found that a control group consuming more fish and vegetables had a lower incidence rate of acne. Therefore, adopting a whole foods diet and reducing the intake of dairy products may help significantly reduce acne [151].

D. Dietary Fiber: Patients with AV consumed daily 30 g of high fiber breakfast cereal (13 g fiber/serving), a significant improvement in the skin condition was shown [151]. Fiber aids elimination of toxins and used hormones from the body. Fruits, vegetables, oats, other whole grains, beans and lentils are good sources. Some soluble dietary fiber components, such as oat bran, pectin, and guar gum, stimulate fecal excretion of bile acids. High fiber intakes promote increased bacterial mass but do not alter the microflora composition [152]. Gastrointestinal dysfunction is an important risk factor for diseases of the sebaceous glands and is correlated with their occurrence and development [153], conversely proper digestion improves acne conditions. One study involving over 13,000 adolescents showed that those with acne were more likely to experience gastrointestinal symptoms such as constipation, halitosis, and gastric reflux. In particular, abdominal bloating was 37% more likely to be associated with acne and other seborrheic diseases [154].

E. Anti-oxidants: Al-Shobaili, et al. revealed that plasma levels of malondialdehyde in acne patients were significantly higher as compared with that of the controls, whereas activities of the antioxidant enzymes superoxide dismutase and catalase were lower. Moreover, total antioxidant capacity was also low in acne patients as compared with that of the controls [56]. Polyphenols are antioxidant molecules found in many foods including nuts, fruits, vegetables, chocolate, wine, and tea. Polyphenols have antimicrobial, anti-inflammatory, and antineoplastic properties. Recent studies suggest that tea polyphenols may be used for reducing sebum production in the skin and for treatment of AV. Again, green tea and green tea-lotus combination topicals could be used to treat skin diseases that are associated with increased sebum secretion, such as AV [155-157]. Apple polyphenols (APP) inhibited Dexamethasone-induced lipid production and expression of sterol response element-binding protein-1 and its target enzymes, acetyl-CoA carboxylase and fatty acid synthase, in the sebocytes. Thus, APP may be useful

to regulate sebum production and may alleviate sebum-involved skin disease [158]. Low vitamin A, E and zinc plasma levels have an important role in the pathogenesis of acne and in the aggravation of this condition. Supportive treatment with these vitamins and zinc in severe acne may lead to satisfactory results [159], [54].

F. *Frequent Cleansing and Sun Protection*: Washing and over-the-counter cleansers are common interventions in AV, but the clinical evidence for their benefit is poorly understood [160]. Cleansers reduced both inflammatory and non-inflammatory acne lesion counts, and might be helpful for acne treatment [161]. In addition to containing dyes and perfumes that can irritate and exacerbate acne, these cleansers often are too harsh and can result in excessive drying of the skin, which leads to overcompensation by the oil glands and ultimately to more oil on the surface of the skin [162]. However, cleansing the acne patient involves several considerations, including matching skin type to the right type of cleanser, optimal times and methods of cleansing, treating parts of the body other than the face, and patient perceptions of the cause and treatment of acne. Soap-free cleansing products that have a similar pH to skin (5.5) are more suitable for people with acne. A reference pH range of 4.5 to 5.5 was considered normal for women, and 4 to 5.5 was considered normal for men. Studies have shown that lowering the pH reduces the inflammatory TH2 response (CD4+ cells, orchestrate protective type 2 immune responses) and quickens barrier function recovery, thereby preventing epidermal hyperproliferation [163]. While sunscreens are often irritants, the best options for young, oily, acne-prone skin tend to have a water or light liquid base. Moisturizing sunscreens are appropriate for patients with dry, sun-damaged skin, as well as those who wear makeup, have other skin diseases, or are easily irritated by products [61].

G. *Avoid Stress/Tobacco*: Stress is a well-attested contributor to AV pathogenesis. The basis for the association between emotional stress and the onset or exacerbation of acne is in several cutaneous neurogenic factors which interact with a pathogenic cascade in acne. Stress stimulates the release of pro-inflammatory cytokines and CRH, leading to increased levels of cortisol. Sleep deprivation associated with modern lifestyle and stress have an important impact on the hypothalamic-pituitary-adrenal axis and in increased secretion of stress-related hormones, and may also be an aggravating factor for acne. Pythagorean Self-Awareness Intervention is a feasible and possibly effective stress management method for AV [165-166]. Clinical evidence and experimental data showed a straight correlation between smoking habit and post-pubertal acne in which the clinically non-inflammatory (atypical) post-adolescent acne is the most frequent [167]. The comedonal form predominates in smokers and is characterized by the presence of micro and macro-comedones and few inflammatory lesions, which led the authors to describe this clinical form as "smoker's face." The sebaceous gland is sensitive to acetylcholine that is stimulated by nicotine. Acetylcholine leads to

cellular modulation and differentiation, inducing hyperkeratinization and influencing sebum production and composition, as well as reducing antioxidant agents and increasing peroxidation of sebum components, such as squalene [168]. Among patients with adolescent acne, the probability to be affected by current acne in smokers was between 2.6–6.3 times higher than in non-smokers [167]. However, it is worth bearing in mind that many successful quitters have found it motivational to watch their skin regain its tone and elasticity just weeks after smoking cessation [169].

Topical drugs

Topical treatment is the mainstay of acne therapy. The most commonly prescribed topical medications for acne include benzoyl peroxide, clindamycin, and retinoids. Despite their effectiveness in treating mild to moderate acne vulgaris, these topical medications are found to be irritating, and are historically associated with poor tolerability and diminished patient adherence. Thus, choosing the right formulation that will be effective and well tolerated is essential. Antibiotics targeting *P. acnes* have been the mainstay in acne treatment for the past four decades. Among them, macrolides, clindamycin, and tetracyclines are the most widely prescribed. Novel formulations that optimize drug concentration and utilize improved delivery vehicles have helped to enhance the tolerability and efficacy, and allow for less frequent application or co-application of drugs that were previously considered incompatible. In the near future, more effective treatments with less side effects are expected. The use of topical anti-androgens, coenzyme-A carboxylase inhibitors, and insulin growth factor-1inhibitors to control sebum production seem promising. Selective RAR-agonists have the potential of becoming an alternative to the currently available retinoid therapy in the management of infundibular dyskeratosis with a better safety profile. Antibiotic use will probably decline as more effective options for controlling *Cutinebacterium acnes* colonization and the inflammation cascade emerge.

Benzoyl Peroxide

Benzoyl Peroxide (BP) has been an important component of topical therapy for acne vulgaris for more than five decades due to its ability to markedly reduce *Propionibacterium acnes* and inflammatory acne lesions and its ability to moderately reduce noninflammatory acne lesions [170]. It has mild sebostatic and keratolytic effects without a concern for the development of drug-resistant bacteria. Studies suggested that AEs at the application site occurred more often in Japanese patients than Western patients, most of the AEs were mild [171], [172]. It is most effective when used in combination with other acne vulgaris therapies [36]. BP is a bactericidal agent. Combining BP with a topical antibiotic in a stable formulation has been proven in clinical trials to reduce total *P. acnes* count by 99.7% after 1 week of therapy, eliminating both susceptible and resistant strains of *P. acnes* [173]. However, we have recently noticed BP's benefits as monotherapy in the treatment of acne. Topical BP also has mild sebostatic effects contributing to its keratolytic activity and efficacy in treating comedonal acne.

BP is available as both over-the-counter and prescription formulations in concentrations of 2.5%, 5%, and 10% [113]. Available preparations include lotions, creams, gels, foams, solutions, cleansing bars, cleansing lotions, cloths, pads, masks, and shaving creams. Each application vehicle has specific instructions for the frequency of use. Combination products with BP and topical antibiotics or adapalene are more effective than either medication used alone [174]. Concentrations of BP above 5% are not recommended for use in adult women. It can also cause photosensitivity and bleaching of clothing [36]. It is used as 2.5%, 4% and 5% concentration in gel base [27]. BP in concentrations of 2.5%, 5% and 10% are equally effective at treating inflammatory acne. However, higher concentrations are associated with more adverse effects. It is useful as monotherapy for mild acne or as an adjunct in the treatment of moderate to severe acne vulgaris [175]. Comedonal acne is more typical in young adolescents, but can occur in combination with inflammatory papules and pustules at any time. Topical retinoids have long been advocated for the treatment of comedonal acne. Adapalene 0.3%- BP 2.5% was found to be effective in patients with severe acne. Clindamycin-BP 1.2%/3.75% gel and clindamycin-BP 1.2%/2.5% gel was both found to be effective in severe acne with an apparent BP-dose response [176]. Clindamycin 1.2%-BP 3.75% gel may afford similar benefits to adapalene 0.3%-BP 2.5% gel in this sometimes difficult to treat patient population [177]. When acupuncture was combined with BP, serum excretion rate in women was reduced compared to BP alone [178]. In addition to use for facial acne vulgaris, cleanser formulations of BP are commonly used for truncal AV due to ease of use on a large body-surface area and to avoid bleaching of fabric. Short contact therapy utilizing a 2-minute skin contact time with BP 9.8% emollient foam used once daily over a 2-week duration was highly effective in reducing the quantity of P acnes organisms on the back and provided comparable colony count reduction to "leave on" therapy using BP 5.3% emollient foam [179]. The FDA classifies benzoyl peroxide as pregnancy risk category C [180] (Figure 3).

Clindamycin

Due to the significant increase of *P. acnes* strains resistant to clindamycin and erythromycin, the use of these substances alone is contra-indicated [181]. *Cutibacterium acnes* (*C. acnes*) can become an exacerbating factor in acne vulgaris, where clindamycin was found to be resistant, as reported by Aoki et.al, 2019 [182]. Clindamycin can be administered into the body by multiple routes. It is available topically as a foam, gel, lotion, or solution for treatment of acne vulgaris. The most common side effects experienced with topical use include pruritis, xeroderma, erythema, burning, exfoliation, or oily skin [183]. Treatment with clindamycin phosphate 1.2% and tretinoin 0.025% resulted in continuous improvement of facial acne over the course of 12 weeks, along with improved QOL and a tolerable safety profile, supporting the use of this combination in clinical practice [184]. Tolerability profile of ClinP/Tret gel is beneficial when combining different topical therapies and formulations in a given patient, as cutaneous irritation is an adverse factor that can reduce adherence and prevent a successful therapeutic

outcome [185]. It is also easy for patients to handle and apply, and has the advantage of not containing BP which can bleach hair and fabrics [186]. ClinP/Tret gel has a favorable safety profile following UV/visible irradiation and a low potential for phototoxicity and photo-allergy, currently available for the once-daily topical treatment of acne [187]. Patients with Fitzpatrick Skin Type V and VI treated with clindamycin phosphate 1.2%/ BP 3.75% gel experienced significant reductions in facial acne severity, lesion counts and PIH severity/distribution. Tolerability was excellent [188]. A triple-combination regimen incorporating oral minocycline (dosed by patient weight), BP foaming cloths 6% QD, and clindamycin phosphate 1.2%/ tretinoin 0.025% gel QD can substantially improve moderate to severe acne vulgaris [189]. Zeichner et al. reported similar cutaneous S/Es with a fixed-dose tretinoin 0.025%/clindamycin phosphate 1.2% gel in combination with a benzoyl peroxide 6% foaming cloth compared with ClinP/Tret gel alone for facial acne [190]. Clindamycin often discussed along with the macrolides but are not chemically related, it belongs to a group of medicines known as lincosamide or lincomycin antibiotics. Clindamycin is pregnancy category B (Figure 4).

Retinoids

Topical retinoids are creams, lotions and gels containing medicine derived from Vitamin A. These compounds result in proliferation and reduced keratinization of skin cells independent of their functions as a vitamin and devoid of bacterial resistance. American Academy of Dermatology (AAD) states "retinoids are the core of topical therapy for acne because they are comedolytic, resolve the precursor microcomedone lesion, and are anti-inflammatory;" further, they "allow for maintenance of clearance" [191]. Local adverse effects, including erythema, dryness, itching, and

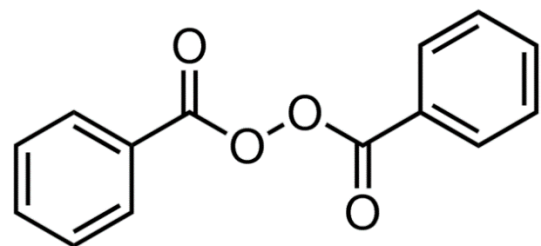


Figure 3: Benzoyl peroxide.

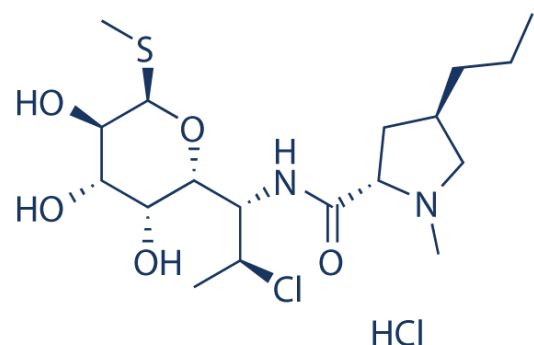


Figure 4: Clindamycin Hydrochloride.

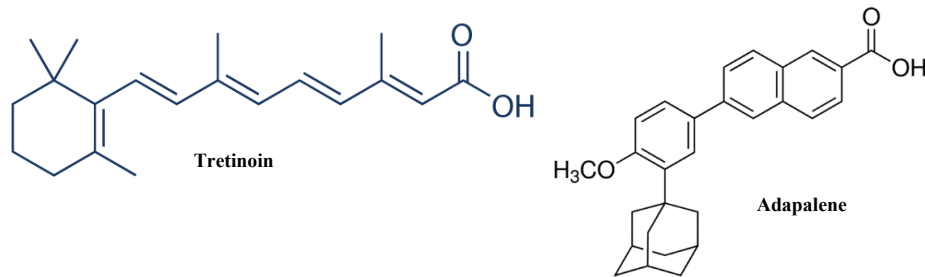


Figure 5: Retinoids.

stinging, occur frequently during the early treatment phase. Their impact varies with the vehicle formation, skin type, frequency and mode of application, use of moisturizers, and environmental factors such as sun exposure or temperature [192]. Retinoids act to normalize desquamation by reducing keratinocyte proliferation and promoting differentiation. Isotretinoin, tretinoin, and tazarotene also suppress Toll-like receptor expression. Blocking these pathways reduces the release of inflammatory cytokines and nitric oxide and inhibits cellular inflammation [191]. Topical retinoids are safe and efficacious for the treatment of AV. They should be used in combination with benzoyl peroxide to optimize results in patients. Adapalene has a superior tolerability profile amongst topical retinoids [193]. Developed in response to concerns about the instability of tretinoin, the naphthoic acid derivative adapalene was found in vitro to be photostable and not degraded in the presence of BP. Again, adapalene/BP was rated as more successful with a significantly greater reduction in all lesions counts compared to any other therapy at the conclusion of the trial [194]. Higher concentrations of retinoids such as adapalene 0.3%/BP 2.5% have shown increased efficacy, particularly among patients with moderately severe and severe acne – a population at high risk for scarring [195]. Adapalene supplied as a 0.1% cream, gel, and lotion and 0.3% gel are prescription only products. It is less irritating compared to other topical retinoids, applied once daily, either in the morning or at bedtime to a clean face. The patient should be advised to wash the face with a gentle cleanser and allow the face to dry thoroughly [50]. Tretinoin 0.05% gel exhibits a greater anti-acne efficacy than adapalene 0.1% gel, but has higher skin irritation potential [196]. Chandrashekar et.al, 2015 stated tretinoin 0.025% nanogel formulation is more efficacious and better tolerated than its conventional 0.05% gel formulation [197]. Harper et.al, 2019 detailed a similar polymeric formulation of tretinoin 0.05% lotion with an incidence of erythema, dryness, and skin burning [198]. Combination of tretinoin 0.05% cream and Aloe vera topical gel (50%) with was well tolerated and significantly more effective than tretinoin 0.05% cream alone for the treatment of mild to moderate acne vulgaris [199]. Deshmukh et. al, 2019 found that topical combination of 1% Nadifloxacin and 0.025% Tretinoin was caused greater reduction in facial acne lesions than 1% Clindamycin and 0.025% Tretinoin in patients of mild to moderate AV. This could be due to the fact that Nadifloxacin is reported to have potent action against *P. acnes*, *Staphylococcus epidermidis*, and Methicillin-Resistant *Staphylococcus aureus* (MRSA), with no cross-resistance [200] (Figure 5) (Table 8).

Azelaic acid

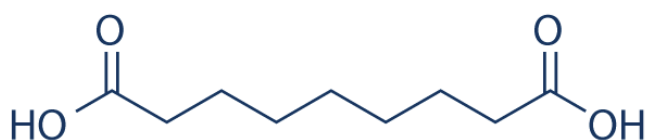
Azelaic acid is a naturally occurring saturated C9-dicarboxylic acid which has been shown to be effective in the treatment of comedonal acne and inflammatory acne, as well as hyper-pigmentary skin disorders [207]. It is an antiacne drug by inhibiting thioredoxin reductase enzyme of *Propionibacterium acnes* that affects the inhibition of bacterial DNA synthesis which occurs in the cytoplasm. Azelaic acid (20% cream or 15% gel) is recommended as the first line of treatment in monotherapy for non-inflammatory and inflammatory acne, applied twice a day [36]. Azelaic acid 15% foam is effective and safe in the treatment of facial acne vulgaris [208]. Treatment with azelaic acid 20% cream significantly improves acne severity and disease-related QoL in adult women [209]. Azelaic acid must penetrate through the stratum corneum to the sebaceous tissue and into cytoplasm by passing through thick peptidoglycan of *P. acnes*. Thus, it is necessary to increase the penetration of azelaic acid that formulated based ethosome. Azelaic acid ethosome-based cream showed better activity to against *P. acnes* than marketed azelaic acid preparation (Zelface® cream) [210]. Combined azelaic acid 20% and salicylic acid 20% are recommended at early stage of treatment if patients have more inflammatory lesions, while trichloroacetic acid 25% chemical peel is recommended if patients have more non-inflammatory lesions. Chemical peeling is effective in controlling mild-moderate acne in SPT III-IV (Fitzpatrick skin type) [211]. Again, a hormonal blockade conducted by ethinylestradiol plus a new generation of progesterone derived of spironolactone with anti-androgenic activity was compared to topical treatment with azelaic acid, it showed better statistical improvement in women with mild to moderate acne [212] (Figure 6).

Dapsone

Topical dapsone is used for both comedonal and papular acne, though there are some concerns with G6PD deficient individuals [27]. Treatment of AV with dapsone gel, 5% requires twice-daily dosing, and some patients may not adhere to this regimen. Dapsone gel, 7.5% applied topically once daily is an effective, safe, and well-tolerated treatment for acne over 12 weeks and offers similar local tolerability compared with vehicle and had a safety and tolerability profile similar to that of twice-daily dapsone gel, 5% in patients aged ≥ 12 years [213,214], [215], [216,217]. However, Monotherapy with dapsone gel, 5% administered twice daily was safe and effective for treatment of facial

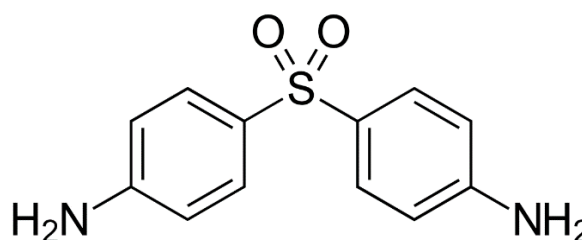
Table 8: News of celebrities who got rid of their acne.

News	Comment
Natalie Portman says going vegan changed everything [201].	The frequency of vegetables and fish intake was significantly higher in the control group than in the acne group [70].
Victoria Beckham eats a lot of salmon [201].	Salmon is rich omega-3 fatty acids. There is some evidence that fish oil supplementation is associated with an improvement in overall acne severity, especially for individuals with moderate to severe acne [202].
Rihanna cuts back on booze. I cut out all alcohol and overdo the water," she said [201].	Among patients with adolescent acne, the probability to be affected by current acne in smokers was between 2.6–6.3 times higher than in non-smokers.
Scarlett Johansson always washes her face and makeup brushes [201]	Antibacterial face washes can have a positive effect in mild acne, but might also irritate more sensitive skin. There is no clear evidence that acne vulgaris is related to poor hygiene or that frequent face washing lessens acne [113]. Acne is unavoidable but can be controlled by regular washing of the face by a pH balancing wash which is available as benzoyl peroxide and salicylic acid face wash [27].
Cameron Diaz wrote that fast food was plaguing her skin. In "The Body Book," Diaz wrote "My acne wasn't totally gone, but it was significantly better." [201]	Plenty of fast-food items are high on the glycemic index, elicit a rapid shift in blood glucose and insulin levels. Insulin also stimulates the synthesis of androgens leading to high sebum production, a recognized correlate of acne severity [12]. On the contrary, low-glycemic-index foods increased SHBG and reduced androgen levels; this is important since higher SHBG levels were associated with lower acne severity [13].
"Whenever it's been really bad, I've gone to the dermatologist to get those cortisone shots. Those are amazing....." Emma Stone [203].	Low doses of corticosteroids, such as prednisone (2.5 or 5mg), can suppress adrenal androgen production and are recommended in late congenital adrenal hyperplasia, acute inflammatory lesions in AFA, and short-term treatment of very severe acne [36]. While short-term use of corticosteroids is associated with mild side effects, long-term use can result in hypertension, peptic ulcer disease, ocular damage, neuropsychiatric effects, hematologic and musculoskeletal effects. Patients need close monitoring and follow up and should also be advised not to exceed the prescribed treatment and to only discontinue use under medical supervision [204,205].
After years of struggling with breakouts, Bella Thorne turned to the powerful anti-acne drug Accutane [203].	Isotretinoin is a vitamin A-derivative 13-cis-retinoic acid, which is the most effective therapy for acne to date. It targets all four processes during acne development, including normalization of follicular desquamation, reduction of sebaceous gland activity, inhibition of the proliferation of <i>Propionibacterium acnes</i> and anti-inflammatory effects. It cured around 85% of patients after an average treatment course of 4 months. However, risk of depression associated with the use of isotretinoin has been a major concern for a long time [107].
"I never used to understand the importance of washing my brushes, but it's so important" Miley Cyrus [203]	With each use, your makeup brushes become coated with more than just residue. They pick up sebum, dead skin and airborne dust and dirt. They need to be cleaned regularly AND properly. If not, all of this debris will build up and negatively affect future makeup applications and decrease the life expectancy of brushes. The most dangerous consequence of dirty brushes – they become a playground for bacteria that can cause skin problems and possible infection [206].

**Figure 6:** Azelaic Acid

acne in women with and well tolerated in patients with all skin phototypes who were treated for moderate acne [218,219]. Dapsone 7.5% gel is a viable option to add to the armamentarium for treatment of truncal AV [220]. Draeos et al. [221] found that Treatment response with dapsone gel, 7.5% in racial subgroups was similar. Tanghetti et al. [222] revealed that once-daily dapsone gel, 7.5% was efficacious for acne regardless of baseline total lesion count, with superior efficacy in females and similar tolerability in males and females. It has been shown to be useful when combined with doxycycline and then alone as maintenance for long periods, with the advantage of having no risk for bacterial resistance in patients with AV [36]. The combination oral doxycycline hyclate 100 mg with topical dapsone 5% gel twice daily is an effective and well-tolerated regimen to treat moderate to severe acne vulgaris. After discontinuation of doxycycline, topical dapsone 5% gel is effective at

maintaining a therapeutic response. Topical dapsone 5% gel can be used effectively for long-term acne maintenance treatment without the risk of developing antibiotic resistance [223]. Incorporation of dapsone in methylprednisolone aceponate 0.1 % ointment broaden the therapeutic options for topical treatment, in particular for patients with chronic inflammatory dermatoses associated with a neutrophilic pathogenesis [224]. Drugs which inhibit cytochrome P-450 should be used with caution in patients receiving dapsone [225]. Careful patient selection and close monitoring during treatment are mandatory to provide safe and effective use of dapsone [226]. Bilosomes as novel vesicular carrier for the cutaneous delivery of the sulfone compound, Dapsone, for topical treatment of acne represented about 1.5-fold higher drug retained in the bilosomes treated skin, compared to dapsone alcoholic solution. [227] (Figure 7).

**Figure 7:** Dapsone

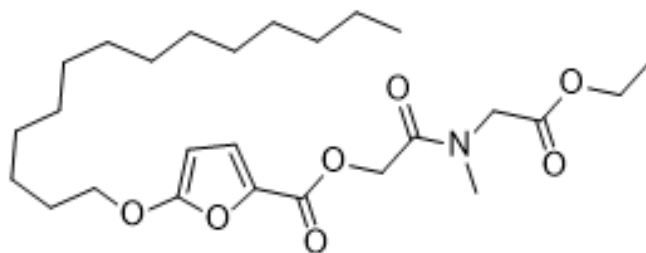


Figure 8: Olumacostat glasaretil

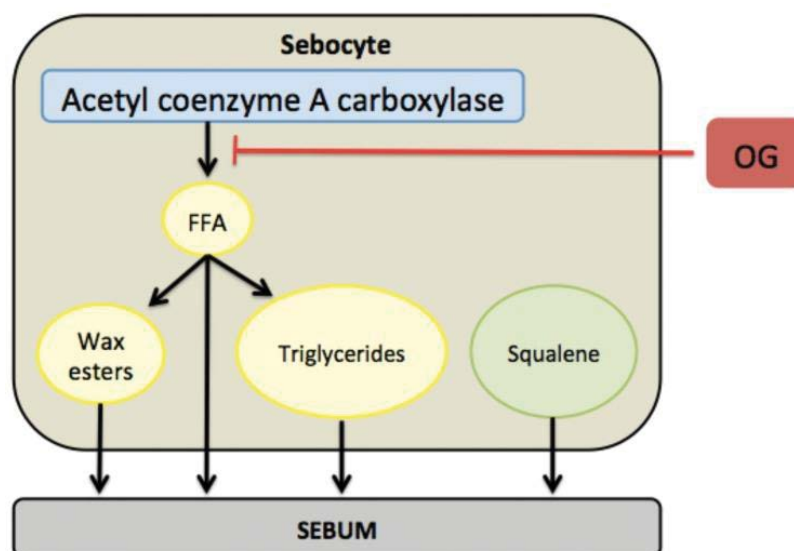


Figure 9: Olumacostat Glasaretil (OG) blocks acetyl coenzyme-A carboxylase in sebocytes to inhibit the production of Free Fatty Acids (FFA) [229].

Acetyl Coenzyme A Carboxylase Inhibitor

The increasing emergence of microbial resistance associated with antibiotics, teratogenicity, particularly associated with systemic isotretinoin, and the need for an adverse drug profile, which can be tolerated by the patient, make the need of new pathogenesis relevant anti-acne agents an emerging issue. The compounds under investigation include olumacostat glasaretil, cortexolone 17 α -propionate, stearoyl-CoA desaturase 1 inhibitors, agents affecting the melanocortin system, omiganan, and minocycline [228]. Olumacostat glasaretil (OG) is a small molecule inhibitor of acetyl coenzyme A (CoA) carboxylase (ACC), the enzyme that controls the first rate-limiting step in fatty acid biosynthesis. Inhibition of ACC activity in the sebaceous glands is designed to substantially affect sebum production, because over 80% of human sebum components contain fatty acids. OG inhibits de novo lipid synthesis in primary and transformed human sebocytes, including the synthesis of triglycerides, diglycerides, cholesteryl esters, wax esters, and phospholipids [222]. OG was well tolerated and showed evidence of efficacy [229]. It reduces both saturated and monounsaturated fatty acyl chains in sebaceous lipids. Topical OG application decreases hamster ear sebaceous gland size and shows efficacy in treating patients with acne vulgaris [230]. Triglycerides and fatty acids together make up the largest portion of sebum content; therefore, OG has the potential to decrease sebum output. Further,

when evaluated in animal models, topical OG consistently reduced sebaceous gland size. Dermira, a biopharmaceutical company, released data from a Phase 2b trial conducted for a topical sebum production inhibitor, OG (formerly DRM01) [228] (Figure 8 and 9).

Topical Anti-androgens

Topical spironolactone may be effective for the treatment of acne patients with increased sebum secretion. The 5% spironolactone topical gel resulted in a decrease in the total acne lesions (TLC) in acne vulgaris, while it had no significant efficacy in the acne severity index [231]. RCTs have shown mixed results in the improvement of acne, which indicates that topical spironolactone gel is not an effective alternative for systemic spironolactone [232]. Cortexolone 17 α -propionate 1% cream was very well tolerated, and was significantly better than placebo regarding TLC [233]. Cortexolone 17 α -propionate competitively inhibits endogenous androgen binding at the human androgen receptor level without inhibiting the skin 5 α -reductase. Cortexolone 17 α -propionate 1% cream was also clinically more effective than tretinoin 0.05% cream but this difference was not statistically significant [124]. Stearoyl-CoA desaturase-1 (SCD-1) catalyzes the formation of delta9-monounsaturated fatty acids from saturated precursors. Upon topical application to the skin of mice as a 1% solution, XEN103 induces pronounced sebaceous

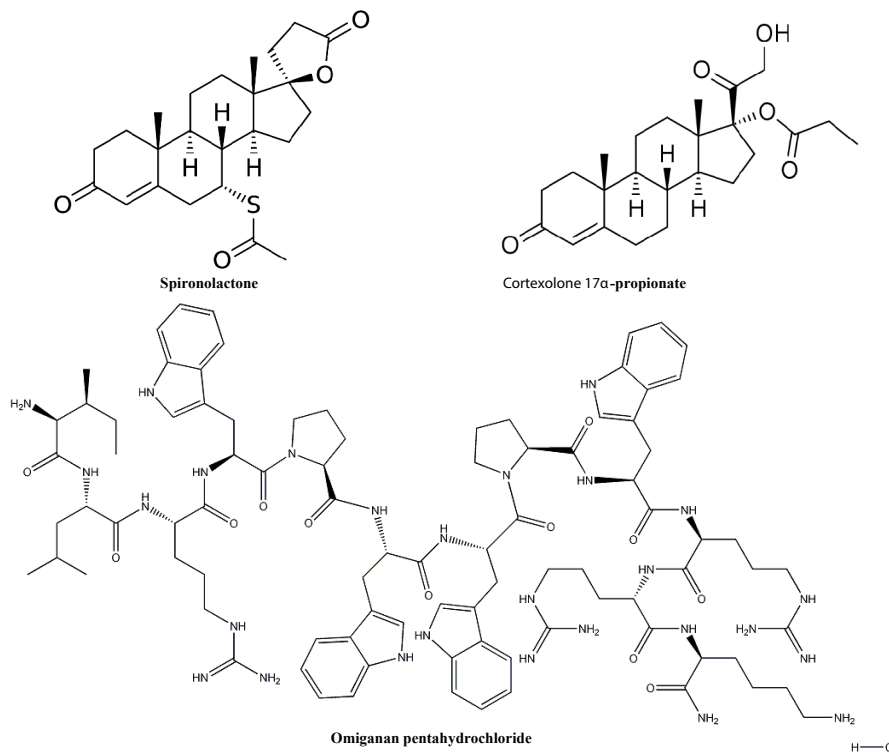


Figure 10: Topical Anti-androgens.

gland atrophy with a rapid onset after a few days of dosing, both sebaceous gland numbers and size being reduced by 50 to 75%, and without any signs of skin irritation [234]. Omiganan pentahydrochloride is a synthetic, cationic, antimicrobial peptide that is being developed for the prevention of catheter-related infections and the treatment of acne and rosacea. It has been demonstrated to be rapidly bactericidal and fungicidal, with significant dose-dependent activity against a broad spectrum of infectious organisms. These results further confirm that the drug has the potential as a topical antimicrobial agent [235] (Figure 10).

Minocycline

Oral tetracyclines-especially doxycycline and minocycline-are frequently prescribed for the treatment of moderate-to-severe acne, given their anti-inflammatory properties and their effect on P. acnes reduction. Minocycline is an effective treatment for moderate to moderately-severe inflammatory acne vulgaris. It is an oral antibiotic, use has lessened due to safety concerns (including potentially irreversible pigmentation), a relatively high cost, and no evidence of any greater benefit than other acne treatments [236]. FMX101 4% is a topical minocycline foam is a new class of topical minocycline products has been developed for the treatment of acne and rosacea that decreases the risk for antibiotic resistance while maintaining safety and efficacy, hydrophilic gel studies reported greater treatment efficacy than the lipophilic foam studies. reduced both inflammatory and noninflammatory lesions and improved Investigator's Global Assessment scores in patients with moderate-to-severe acne [237,238]. Once-daily topical application of minocycline foam 4% did not lead to significant systemic exposure to minocycline. It appears to

be a well-tolerated treatment option for individuals with moderate-to-severe acne [239]. BPX-01) was developed to directly deliver minocycline through the epidermis and into the pilosebaceous unit to achieve localized treatment with lower doses of drug [240]. However, because BPX-01 (another topical minocycline in trial) is topical and exhibits negligible systemic exposure, the likelihood of adverse events associated with oral minocycline use is much lower. BPX-01 2% formulation is a promising treatment for moderate-to-severe nonnodular, inflammatory acne vulgaris in both reductions of inflammatory lesions and also overall improvement in facial acne according to IGA [241]. (Figure 11)

Oral drugs for acne management

Not all acne clears up with topical medications. Oral medications, also called systemic medications, work internally to improve the skin. Persistent or severe cases of acne are difficult to control, and in the majority of cases requires oral medications. A hot, humid climate with an

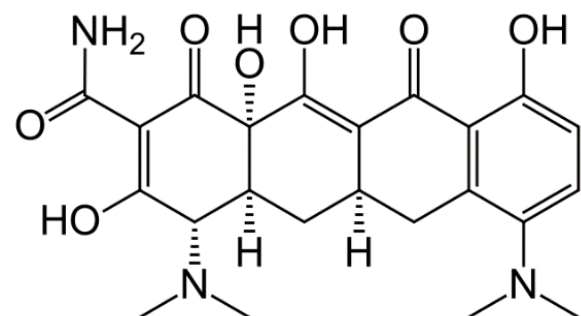


Figure 11: Minocycline

increased risk of sweating can also make it worse. Severe acne (sometimes called cystic acne or nodular acne) creates large, deep, inflamed breakouts. Topical medications can't get deep enough to effectively treat these types of blemishes. All oral acne medications are prescription only. There are no over-the-counter alternatives. People who shave should use safety razors with a sharp blade or an electric shaver. Most patients on oral antibiotics should notice improvements after about 6 weeks. A course may last from 4 to 6 months. Pregnant or breastfeeding mothers should take an erythromycin instead of tetracycline. Long-term oral antibiotic use in acne may be associated with a variety of adverse effects including antibiotic resistance, pharyngitis, inflammatory bowel disease, and breast and colon cancer.

Isotretinoin

Isotretinoin is a retinoic acid derivative mostly used in the treatment of cystic acne vulgaris [242]. Oral isotretinoin is FDA-approved for the treatment of severe recalcitrant AV but can also be used to treat patients with moderate acne that is either treatment-resistant or relapses quickly after discontinuation of oral antibiotic therapy. Several studies have shown that isotretinoin effectively decreases sebum production, the number of acne lesions, and acne scarring [124]. The treatment for the average patient is carried out during two to ten months [243]. Isotretinoin is the most effective treatment available, but serious adverse effects, including a possible association with depression and suicide, limit its use, further studies are needed to identify those patients who would benefit from an early referral to a mental health professional when Isotretinoin is initiated [244]. However, Huang et.al, 2017 revealed that Isotretinoin treatment for acne does not appear to be associated with an increased risk for depression. Moreover, the treatment of acne appears to ameliorate depressive symptoms [245]. Botsali et al. [246] further ensured an improvement for neurocognitive functions in isotretinoin patients and none of them was evaluated as depressive by the psychiatric examination. iPLEDGE is the mandatory regulatory program for isotretinoin in the United States, aimed to prevent isotretinoin-related teratogenicity [247]. Isotretinoin is still the best treatment for severe nodulocystic acne. However, it must be taken into consideration its teratogenic effect on pregnant women and its association with inflammatory bowel disease, depression and suicidal ideas [248]. Soyuduru et al. [249] found that five months of isotretinoin therapy in AV patients causes insulin resistance and the increase in insulin resistance is not dependent on age, BMI, BFM, and lipid levels of these patients. Isotretinoin can induce hyperhomocysteinemia and decreased serum folic acid level, which may be a risk for cardiovascular disease and thrombosis, as well as psychoses. Van et.al, 2019 revealed a study in Vietnam where a low dose isotretinoin treatment had effectiveness in decrease the severity of disease without significant changes in the plasma homocysteine level as well as the serum folic acid level [250]. Fouladgar et al. [251] stated that corneal sensitivity decreases after three months of treatment with isotretinoin. This decrease is more pronounced at higher ages and in women. Approximately 80% of pregnant women are exposed to isotretinoin within the recommended 30

days of contraception or during pregnancy. North America and the European Union, implemented the pregnancy prevention program [252]. Tasli et al. [253] stated complaint of nasal obstruction. Conventional and low dose isotretinoin regimens are associated with increased dermcidin (an antimicrobial peptide secreted by sweat glands that attacks any bacteria on our skin) expression [254]. Reduced dermcidin concentration in sweat in patients with inflammatory acne may permit proliferation of *P. acnes* in pilosebaceous units, resulting in progression of inflammatory acne [255]. Isotretinoin was the main component found in milk 10 to 12 hours after a dose while the metabolite was the primary component in milk 22 to 24 hours after the previous dose [256]. A review of adverse reaction reports on retinoids causing a breast reaction submitted to a French pharmacovigilance center found 22 cases of gynecomastia was associated with isotretinoin use. Fourteen of the cases were gynecomastia, 6 were galactorrhea and 2 were of both gynecomastia and galactorrhea. Gynecomastia and/or galactorrhea was unilateral for almost half of the reported retinoid cases [257]. Exposing to isotretinoin among pregnant women has still occurred due to detrimental adherence to risk reduction programs which resulted in live-born infants with different kinds of abnormalities. Despite the known serious adverse effect of isotretinoin, the use of drug was not based on the guidelines in some cases, which needs more attentions to prevent the severe drug related problems [258]. (Figure 12)

Spirolactone

Spirolactone, a synthetic 17-lactone steroid, acts as a non-selective mineralocorticoid receptor antagonist with moderate affinity for both progesterone and androgen receptors [259]. It is an effective second-line treatment option for post-adolescent acne, with a low risk of short-term adverse effects such as hyperkalemia [260]. A reduction in sebum may be achieved by blocking dihydrotestosterone binding to the androgen receptor within sebocytes and inhibiting androgen-induced sebocytes proliferation. The systemic effects of spironolactone on adrenal synthesis of androgen precursors may also contribute to clinical efficacy, although at therapeutic doses this may be unlikely. The diuretic effect of spironolactone may benefit women who experience a premenstrual acne flare associated with fluid retention [261]. The safety of long-term spironolactone use is well established given that it has been approved by the U.S. FDA since 1960. Because androgens mediate increased sebum production, they have been implicated in the pathophysiology of acne which led to the current acceptance of spironolactone as a non-antibiotic alternative to

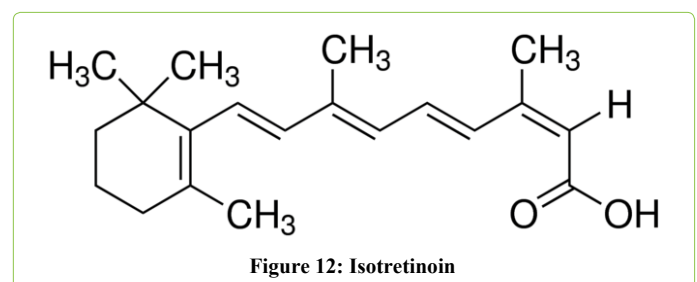


Figure 12: Isotretinoin

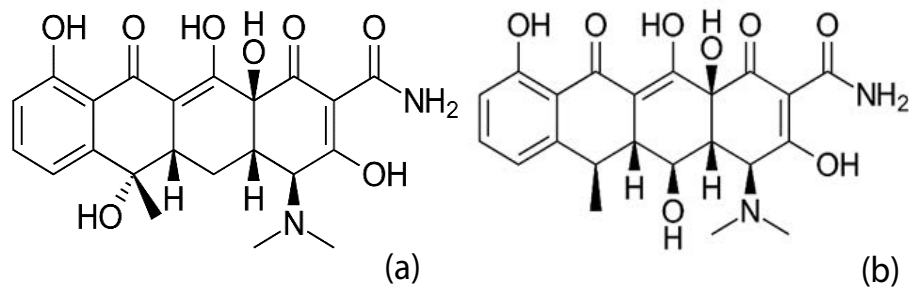


Figure 13: (a) Tetracycline and (b) Doxycycline

traditional systemic treatments for women with acne [232]. Spironolactone regulates sebaceous gland activity by blocking androgen receptor. It is a valuable alternative in women with acne in whom oral isotretinoin has failed. Combined oral contraceptives and spironolactone are good options [262]. First and second-generation oral contraceptives decrease the efficacy of spironolactone, confirming the interest of using two third or fourth-generation oral contraceptives [263]. In monotherapy, 80% of the patients present menstrual irregularity. The combined use of spironolactone with topical retinoid seems to provide a superior response to the retinoid treatment isolated in adult female acne. It can be used to promote androgen blockade in patients using levonorgestrel intrauterine devices or to increase androgen blockade in those who opt for combined oral contraceptive pills. A retrospective study of spironolactone found that there is no need for periodic control of potassium levels in young women, who do not have nephropathies, and are not users of other medications that may increase potassium levels [36]. Spironolactone (25 mg per day) can also be used in males. It decreases the production of androgens and blocks the actions of testosterone. If given to females, then pregnancy should be avoided because the drug can cause feminization of the fetus [27]. For this, spironolactone is classified as a Pregnancy Category C. Without the need for regular blood testing or the risk of severe teratogenicity, spironolactone is an attractive alternative to treatment with isotretinoin [232]. Spironolactone may have similar clinical effectiveness to that of oral tetracycline-class antibiotics [264]. A study shows the effectiveness of spironolactone to treat acne in Asian women, with a 47% good response using an initial dose of 200 mg per day, then reducing the dose every 4 weeks. Spironolactone's side effects are dose-dependent, and the most frequent are increase of diuresis, headache, dizziness, menstrual irregularity, breast pain, fatigue, and hyperpotassemia [262].

Oral antibiotics

Oral antibiotic medications are commonly prescribed as second-line therapy for patients with mild-to-moderate acne that is not adequately controlled with topical agents alone and oral antibiotics have been a mainstay in the treatment of acne for decades and function by exerting an antibacterial effect by reducing the follicular colonization of *Propionibacterium acnes*. Systemic antibiotics also have anti-inflammatory and immunomodulatory properties. Tetracyclines, including sub-antimicrobial dose doxycycline,

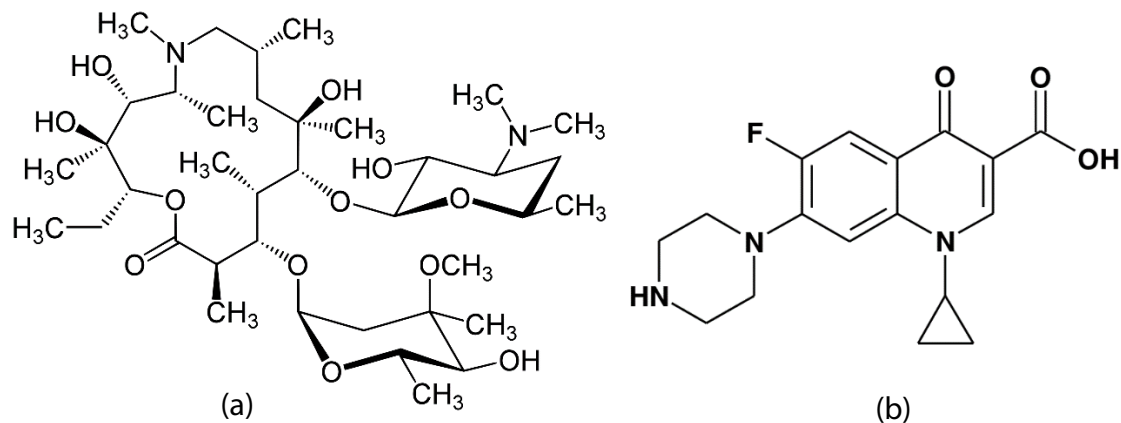
macrolides (notably azithromycin), trimethoprim-sulfamethoxazole, cephalosporins, and fluoroquinolones as treatment options for acne vulgaris. Antibiotic use for acne not only promotes resistance in *Propionibacterium acnes*, but also affects other host bacteria with pathogenic potential. [265,266]. Limiting systemic antibiotic use may also reduce the risk of inflammatory bowel disease (for tetracyclines), pharyngitis (for tetracyclines), *C. difficile* infection, and candida vulvovaginitis; however, studies have shown that these associations are limited. Penicillin, erythromycin, and cephalosporin are thought to have the best safety profile during pregnancy. There are three categories of antibiotic agents that range from those that are likely to reduce the effectiveness of OCPs (rifampin), those that are associated with OCP failure in three or more reported cases (ampicillin, amoxicillin, metronidazole, and tetracycline), and those that were associated with OCP failure in at least one case report (cephalexin, clindamycin, dapson, erythromycin, griseofulvin, isoniazid, phenoxymethylpenicillin, talampicillin, and trimethoprim) [124]. (Figure 13)

Tetracycline treatments, which include minocycline, doxycycline, and tetracycline, are considered first-line therapy in patients with moderate-to-severe inflammatory acne except in certain circumstances including pregnancy, age < 8 years, or known allergy [267]. Tetracycline medications including minocycline and doxycycline are classified as FDA pregnancy category D. Tetracycline agents should not be used during pregnancy because use during the second and third trimester is known to cause discoloration of the teeth and bones [268,269]. GI side effects, including "pill esophagitis," are perhaps the most common concerning side effect associated with the use of oral doxycycline [270]. Oral azithromycin pulse therapy may be a good alternative to doxycycline in the management of acne for those unable to tolerate doxycycline [271] (Table 9).

Azithromycin, 500 mg thrice weekly for 12 weeks, is a safe and effective treatment of acne vulgaris with excellent patient compliance with few S/Es [272,273]. Oral desloratadine had antiacne properties, and when combined with azithromycin plus isotretinoin protocol, it significantly improves severe acne lesions and minimizes the ADEs [274]. Nakase et al. [275] reported low-level fluoroquinolone-resistant mutants with the Ser101Leu or Asp105Gly substitution in Gyr A could be obtained from selection with ciprofloxacin and levofloxacin during in vitro mutation experiments. Other antibiotics such as

Table 9: Factors Differentiate Doxycycline and Minocycline for The Treatment of Acne Vulgaris [270]

Point of Comparison	Study Results
Phototoxicity	Minocycline exhibits negligible photosensitivity while doxycycline exhibits dose-related phototoxicity.
Vestibular side effects	Vestibular side effects, such as vertigo and dizziness, are not characteristic side effects associated with doxycycline use. Minocycline-associated vertigo usually becomes evident after the first dose or within the first few doses, which allows discontinuation of therapy should this side effect occur.
Efficacy comparisons	Although both minocycline and doxycycline have a long overall track record of widespread use with well-recognized efficacy, and safety when used to treat AV, prescription tracking data as depicted above has more recently shown that doxycycline is most commonly prescribed by dermatologists, followed by immediate-release minocycline formulations and extended-release minocycline tablets.
Other adverse reactions	potentially serious adverse effects that have been reported with minocycline and are very unlikely or nonexistent with doxycycline. These include drug-associated lupus-like syndrome, autoimmune hepatitis, and drug hypersensitivity syndrome with associated systemic manifestations (i.e., hepatitis, pneumonitis), in addition to other minocycline-specific side effects, such as vertigo/dizziness and patterns of cutaneous and/or mucosal hyperpigmentation.

**Figure 14:** (a) Azithromycin and (b) Ciprofloxacin

amoxicillin, erythromycin and bactrim are sometimes used, and if bacterial overgrowth or infection is masquerading as acne, other antibiotics such as ciprofloxacin may be used in pseudomonas related 'acne' [27]. Metronidazole gel (2%) is an effective, safe, and well-tolerated topical medication for moderate AV. Its mechanism of action is thought to be associated with its anti-inflammatory, immunosuppressive, and/or antimicrobial properties [266]. Metronidazole has an excellent record of safety during pregnancy and is frequently used as the treatment of choice for several common non-dermatologic infections during pregnancy [267] (Figures 14 and 15).

Oral Contraceptive Pills (OCPs)

Currently, there are three types of oral contraceptive pills: combined estrogen-progesterone, progesterone only and the continuous or extended use pill. Use of combined pills for acne has been formally approved by the FDA for specific brands. The majority of women take OCP's to prevent pregnancy, but 14% used them for non-contraceptive reasons [278]. The beneficial effect of OCPs is related to a decrease in ovarian and adrenal androgen precursors; to an increase in SHBG, which limits free testosterone; and to a decrease in 3 α -androstenediol glucuronide conjugate, the catabolite of DHT formed in peripheral tissues (Figure 15) [279]. There are now four different combined oral contraceptive pills that are FDA approved for the treatment of acne since its first introduction in 1960. Hormonal therapies are effective and well tolerated options for the treatment of acne vulgaris

in adolescents with and without endocrine disorders. They can be used as monotherapy or in conjunction with benzoyl peroxide, topical retinoic acid, or antibiotics [280]. In the case of hormonal disturbances, the use of hormonal contraception not only improves the cosmetic situation of the patient but is also necessary to decrease the risks related to hyperandrogenemia [281]. According to WHO recommendations, the contraindications to oral contraception are as follows: pregnancy, breast feeding, history of deep venous thrombosis and thromboembolic event, active liver disease, smoking after the age of 35 years, migraine, breast cancer, hypertension, diabetes mellitus with vascular changes, and long-term immobilization [282]. There was a significant reduction in the expression of TLR-2 (Toll-like receptor expression) in the skin of adult females with facial acne who used azelaic acid 15% gel or combined oral contraceptive (drospirenone+ethinylestradiol). Rocha et al. [283] suggested a possible anti-inflammatory effect of oral contraceptive and azelaic acid in AFA via modulation of this receptor. Contraceptive pills can have side effects such as headaches, breast tenderness and nausea. The pills that reduced acne had ethinyl estradiol in them, combined with one of the following drugs: levonorgestrel, norethindrone, norgestimate, drospirenone, cyproterone acetate, chlormadinone acetate, dienogest or desogestrel. Cyproterone acetate has not been approved for contraceptive use in Germany, but it can be prescribed for the treatment of acne [89]. Cyproterone acetate (2 mg of cyproterone acetate and 0.35 of ethinyl estradiol) after

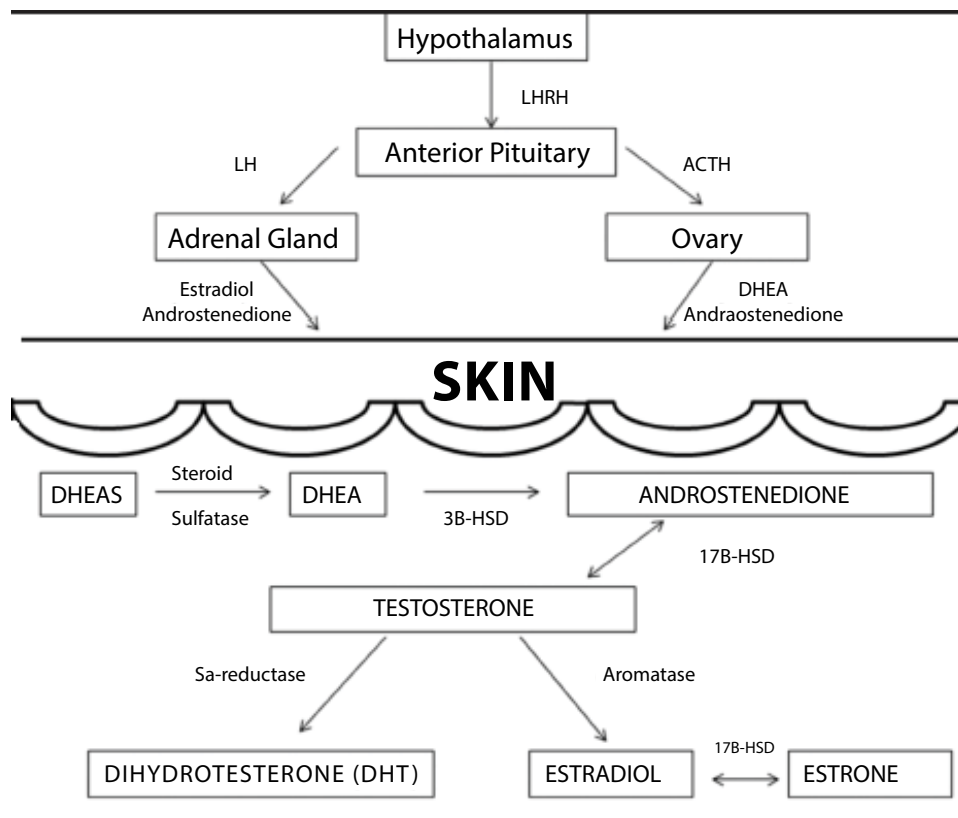


Figure 15: Hormonal regulation of skin pathogenesis [300]. Intracrine secretion involves the synthesis of active androgens in peripheral organs, such as the skin, where the androgens exert their action in the same cells where synthesis takes place without release into the general circulation. A large portion of androgens are also synthesized in the skin from inactive adrenal precursors including, dehydroepiandrosterone (DHEA), DHEA-sulfate (DHEA-S), and androstenedione. Besides sebaceous glands, other androgen-sensitive components of skin are hair follicles, sweat glands, epidermis, and dermis, containing enzymes responsible for converting DHEA, DHEA-S, and androstenedione into the potent androgens dihydrotestosterone (DHT) and testosterone. DHT and testosterone are the major androgens that interact with the androgen receptors on sebaceous glands with DHT being 5 to 10 times more potent than testosterone. This conversion of inactive adrenal precursors to potent androgen occurs in sebaceous glands in the presence of several key steroidogenic enzymes: 3-Beta-hydroxysteroid dehydrogenase (3B-HSD), 17-Beta-hydroxysteroid dehydrogenase (17B-HSD), and 5 α -reductase. Estrogen is known to suppress sebum production when given in sufficient amounts. Other mechanisms for estrogen's effect include direct opposition effect on testosterone and inhibition of testosterone secretion. In addition, through the metabolization of estrogen in the liver, estrogen increases sex hormone-binding globulin (SHBG). SHBG has a high affinity for testosterone and will bind to it preferentially over estrogen. Since testosterone and its conversion to DHT are the primary androgens in acne, increased SHBG leads to improvement in acne.

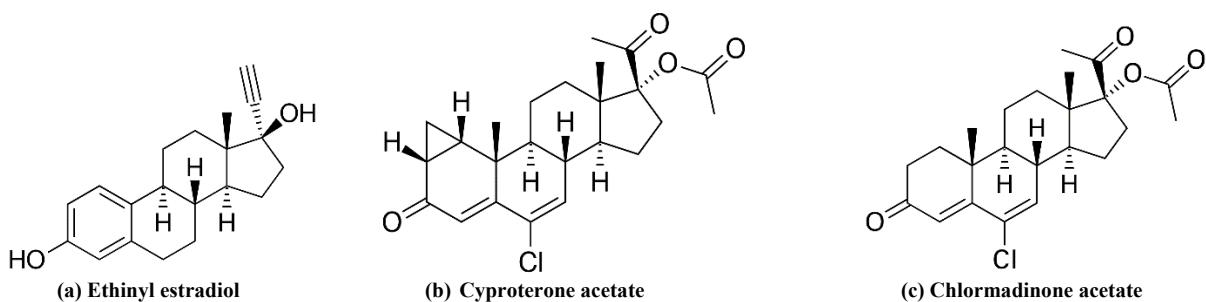


Figure 16: Hormonal contraceptives.

3 months of treatment caused visible improvement in acne in 40%. More than 85% of patient finished the study, which suggests very good compliance and tolerability [284]. Animal studies showed that cyproterone acetate in high doses only is associated with congenital malformations. There is a possibility of abnormal sexual differentiation of the fetus or other teratogenic effects [285]. Chlormadinone acetate was more effective in the treatment of acne than levonorgestrel and was more antiandrogenic than dienogest [286]. ethinyl

estradiol/chlormadinone acetate 30 mcg/2 mg once daily is more effective for the treatment of acne and dysmenorrhea in women with mild to moderate AV and dysmenorrhea than ethinyl estradiol/ drospirenone 30 mcg/3 mg [286] (Figure 16).

Laser therapy

Laser therapies are increasingly becoming part of or an adjunct to the medical treatment of active acne and

are a useful treatment modality. Studies of lasers in the treatment of acne, including erbium glass, Nd:YAG, pulse dye laser (PDL), potassium titanyl phosphate (KTP) laser, and laser-based photodynamic therapy, have been published [287,288]. Lasers including infrared wavelengths and pulsed dye lasers; light devices including blue light, red light, and broadband light; and photodynamic therapy with amino-levulinic acid and methyl-aminolevulinic acid have been shown to be effective in the treatment of acne vulgaris. The optimal outcomes are achieved with photodynamic therapy combined with medical therapy. Acne scarring has been best treated with lasers, including non-ablative infrared lasers, fractional non-ablative and ablative laser resurfacing, and most recently needle-based radiofrequency devices. Unique combination of lasers appears to be safe in patients with Fitzpatrick Skin Type IV, and might be useful in treating moderate-to-severe acne vulgaris. Kang et al. [289] stated that approximately 80% of the patients reported overall satisfaction. Laser therapy is advantageous because it is an in-office treatment, which ensures patient adherence to therapy. In addition, it offers no systemic side effects that might complicate treatment when using oral acne medications. Although many different lasers have been studied for the treatment of acne, only a few studies to date have evaluated a combination of lasers, which include PDL with either a 1,064-nm Nd:YAG or a 1,450-nm diode laser. Lasers studied include the 1,540-nm erbium: glass laser, 1,550 nm fractionated erbium: glass laser, pulsed-dye laser (PDL), q-switched 1,064-nm neodymium-doped yttrium aluminum garnet (Nd:YAG) laser, fractional 1,320 nm Nd:YAG laser, 1,450 nm diode laser, and 532-nm potassium titanyl phosphate laser. In addition, the 1,450 nm diode laser has been shown to reduce sebum production. The novel IPL filter at wavelength of 400-600 nm and 800-1,200 nm provides an effective option to treatment of inflammatory acne lesions, especially for Pillsbury I-II acne patients, with minimal reversible side effects, such as transient post-inflammatory pigmentation. Intense pulsed light (IPL) has become a well-recognized method in the treatment of acne vulgaris [290]. Various types of lasers have been utilized in the treatment of scars since the 1980s, beginning with continuous wave argon, CO₂, and Nd:YAG 1064 lasers, followed by the application of PDL and Er:YAG lasers for scar revision [291]. Most recently, fractional photothermolysis with ablative and non-ablative fractionated lasers have found use as effective treatments for scars. For hypertrophic scars and keloids, the most common non-ablative laser has been the pulsed dye laser (PDL: 585 to 595 nm). For atrophic facial scars, the most commonly used non-ablative lasers are Nd:YAG and 1450 nm diode laser. One study reported an improvement of 40 to 45% with 1320-nm Nd:YAG or 1450 nm diode laser treatment after an average of three consecutive monthly treatment sessions, as assessed by patient satisfaction surveys, histologic evaluations, and skin texture measurements. Non-ablative lasers have minimal downtime and produce gradual results, with the most significant improvement noted between 3 and 6 months following the final laser treatment [292]. PDL is effective in improving the vascularity, pliability, color, and height of hypertrophic scars and keloids. Previous studies have

reported a 57% to 83% improvement in clinical appearance and texture of hypertrophic scars after one to two PDL treatments [293,294]. Non-ablative fractional lasers (NAFL) have been shown to significantly improve the pigmentation and thickness of surgical scars, atrophic scars, hypertrophic scars, and hypopigmented scars. A study by Tierney et al. comparing 1550 nm NAFL to 595 nm PDL for the treatment of surgical scars showed that NAFL outperformed PDL and 83% of patients preferred the half of the scar treated with a non-ablative fractional laser [295,296]. A study by Niwa et al. [291] examined NAFL in the treatment of hypertrophic scars and found 26% to 75% clinical improvement after two to three treatment sessions done at 4-week intervals. Ablative laser resurfacing, with CO₂ or Er:YAG lasers, has been shown to be effective for traumatic and surgical scars, especially when resurfaced within 6 to 10 weeks after trauma or surgery or even immediately after surgery. CO₂ and Er:YAG lasers are also effective for atrophic scars due to their ability to smooth scar texture and stimulate collagen production within facial atrophic scars, although patients must consider the potential for significant downtime as re-epithelialization typically takes 4-7 days with Er:YAG and 7-10 days with the CO₂ laser. While requiring more downtime, ablative lasers usually produce a higher degree of clinical improvement [297,298]. For acne scars, previous head-to-head studies have suggested that CO₂ laser produces superior results while Er:YAG is better tolerated with less downtime. Raised scars and shallow boxcar scars improve the most with laser resurfacing, while icepick scars are more challenging to treat and may necessitate secondary resurfacing. Non-ablative lasers are also useful for acne scars [297,299, 301-303].

Epilogue

A better understanding of the pathophysiological mechanisms driving acne has allowed for the development of more effective topical and systemic therapies. These can be prescribed in logical combinations to target each relevant pathological factor and thus ensure optimal acne management. Each patient should receive education regarding acne and the available treatment options. A realistic explanation of the benefits, risks and expected outcomes of each therapy must be provided to promote autonomy. Patients also need to understand that, although most cases of acne can be cleared with available treatments, therapy requires time, and in the early weeks of treatment their acne may worsen. However, with frequent reassurance and follow-up, many patients will comply with treatment and achieve an acceptable outcome. Maintenance therapy is an important consideration as acne represents a chronic disease and frequently recurs without an ongoing treatment regimen. Among all pathogenetic factors of acne, inflammation seems to be rediscovered and anti-inflammatory concepts seem to become the new trend of systemic and topical acne treatment. Acne scars may have a damaging effect on a person's physical, mental, and social well-being. Although a wide range of treatments are used, there is a lack of high-quality evidence on which are the most effective for acne scars. Despite the interest on the development of topical treatments for acne in the last decades, systemic treatment is still a milestone, especially in the treatment of moderate-to-severe scarring types of the

disease. The establishment of new systemic drugs for acne is based on the consideration of successes and pitfalls of the past and the emerging knowledge of the future.

Chapter Summary

Acne is estimated to affect approximately 10% of the global population, making it the eighth most prevalent disease worldwide. Several studies have confirmed that acne can affect a person's quality of life, self-esteem, and mood in an adverse manner. Acne treatments take a considerable share of dermatology OTC product market. Also, increasingly various prescription acne treatments are becoming qualified as OTC products due to their history of long-term safety and efficacy. The issue of antibiotic resistance also impacts the prescribing patterns and treatment algorithms. The standard of care for the treatment of mild-to-moderate acne still lies with topical therapies. Poor adherence is one of the critical and negatively impacting factors affecting acne treatment outcomes. Moreover, limited patient education and awareness about acne treatment is also a roadblock to successful treatment. The acne therapy market is moving from mono therapy towards combination therapy options. The most likely reason is higher efficacy of combinations that consider the multifactorial pathogenesis of acne, reduced resistance levels, and the ease of single product use versus two separate mono therapies. Laser and light modalities, although not sufficiently studied for first-line use, show promise for the future.

Acknowledgement

It's a great honor and gratitude to be pharmacists in research and education process. All pharmacists, officials, journalists, magazine analysts and associates that I met in this purpose, were very kind and helpful. I'm thankful to Isabel Cristina Valente Duarte de Sousa, M.D. Dermatology; Hospital ABC Santa Fe, Mexico City Area, Mexico for her precious inputs. I'm also grateful to seminar library of Faculty of Pharmacy, University of Dhaka and BANSDOC Library, Bangladesh for providing me books, journal and newsletters. The greatest help was from students and colleagues who continually supported me in collection and data extraction from books, journals, newsletters and precious time in discussion followed by providing information on different types of cosmetics in use. A portion of this article is long been lectured as course material. So, it is very much helpful for me to deliver better than before as many more things are studied.

Compliance with the Ethical Issues

- **Ethics approval and consent to participate**

Animal and Human experiment: N/A

Human Data Submission Approval: N/A

- **Consent for publication**

Consent to publish Individual Person's data: N/A

- **Availability of data and materials**

Data sharing: Please contact author for data requests

- **Competing interests**

The author declares that he has no competing interests

References

1. Liu PF, Hsieh YD, Lin YC, Two A, Shu CW, et al. (2015) Propionibacterium acnes in the pathogenesis and immunotherapy of acne vulgaris. *Curr Drug Metab* 16: 245-54.
2. Valente Duarte De Sousa IC (2019) New and emerging drugs for the treatment of acne vulgaris in adolescents. *Expert Opin Pharmacother* 20: 1009-1024.
3. Bellew S, Thiboutot D, Del Rosso JQ (2011) Pathogenesis of acne vulgaris: what's new, what's interesting and what may be clinically relevant. *J Drugs Dermatol* 10: 582-585.
4. Aydemir EH (2014) Acne vulgaris. *Turk Pediatri Ars* 49: 13-16
5. Gollnick HP (2015) From new findings in acne pathogenesis to new approaches in treatment. *J Eur Acad Dermatol Venereol* 5: 1-7.
6. Cong TX, Hao D, Wen X, Li XH, He G, et al. (2019) From pathogenesis of acne vulgaris to anti-acne agents. *Arch Dermatol Res* 311: 337-349.
7. Yang JH, Yoon JY, Kwon HH, Min S, Moon J, et al. (2017) Seeking new acne treatment from natural products, devices and synthetic drug discovery. *Dermatoendocrinol* 9.
8. Beylot C (2002) Mechanisms and causes of acne. *Rev Prat* 52: 828-830.
9. Eichenfield LF, Del Rosso JQ, Mancini AJ, Cook-Bolden F, Stein Gold L, et al. (2015) Evolving perspectives on the etiology and pathogenesis of acne vulgaris. *J Drugs Dermatol* 14: 263-272.
10. Keri JE, Rosenblatt AE (2008) [In Process Citation]. *J Clin Aesthet Dermatol* 1: 22-26.
11. Kucharska A, Szmurło A, Sińska B (2016) Significance of diet in treated and untreated acne vulgaris. *Postepy Dermatol Alergol* 33: 81-6.
12. Reynolds RC, Lee S, Choi JY, Atkinson FS, Stockmann KS, et al. (2010) Effect of the glycemic index of carbohydrates on Acne vulgaris. *Nutrients* 2: 1060-1072.
13. Pappas A (2009) The relationship of diet and acne: A review. *Dermatoendocrinol* 5: 262-267.
14. Nguyen QG, Markus R, Katta R (2016) Diet and acne: an exploratory survey study of patient beliefs. *Dermatol Pract Concept* 6: 21-27.
15. Romańska-Gocka K, Woźniak M, Kaczmarek-Skamira E, Zegarska B (2016) The possible role of diet in the pathogenesis of adult female acne. *Postepy Dermatol Alergol* 33: 416-420.
16. Emiroğlu N, Cengiz FP, Kemeriz F (2015) Insulin resistance in severe acne vulgaris. *Postepy Dermatol Alergol* 32: 281-285.
17. Mishra JS, More AS, Kumar S (2018) Elevated androgen levels induce hyperinsulinemia through increase in Ins1 transcription in pancreatic beta cells in female rats. *Biol Reprod* 98: 520-531.
18. Assaf HA, Abdel-Maged WM, Elsadek BE, Hassan MH, Adly MA, et al. (2016) Survivin as a Novel Biomarker in the Pathogenesis of Acne Vulgaris and Its Correlation to Insulin-Like Growth Factor-I. *Dis Markers* 2016: 7040312.
19. Çerman AA, Aktaş E, Altunay İK, Arıcı JE, Tulunay A, et al. (2016) Dietary glycemic factors, insulin resistance, and adiponectin levels in acne vulgaris. *J Am Acad Dermatol* 75: 155-162.
20. Rahaman SMA, De D, Handa S, Pal A, Sachdeva N, et al (2016) Association of insulin-like growth factor (IGF)-1 gene polymorphisms with plasma levels of IGF-1 and acne severity. *J Am Acad Dermatol* 75: 768-773.
21. Melnik BC (2015) Linking diet to acne metabolomics, inflammation, and comedogenesis: an update. *Clin Cosmet Investig Dermatol* 8: 371-388.
22. Juhl CR, Bergholdt HKM, Miller IM, Jemec GBE, Kanters JK, et al. (2018) Dairy Intake and Acne Vulgaris: A Systematic Review and Meta-Analysis of 78,529 Children, Adolescents, and Young Adults. *Nutrients* 10.
23. Danby FW (2011) Acne: Diet and acnegenesis. *Indian Dermatol Online J* 2: 2-5.
24. Kim H, Moon SY, Sohn MY, Lee WJ (2017) Insulin-Like Growth Factor-1 Increases the Expression of Inflammatory Biomarkers and Sebum Production in Cultured Sebocytes. *Ann Dermatol* 29: 20-25.

25. Cappel M, Mauger D, Thiboutot D (2005) Correlation between serum levels of insulin-like growth factor 1, dehydroepiandrosterone sulfate, and dihydrotestosterone and acne lesion counts in adult women. *Arch Dermatol* 141: 333-338.
26. Adebamowo CA, Spiegelman D, Berkey CS, Danby FW, Rockett HH, et al. (2008) Milk consumption and acne in teenaged boys. *J Am Acad Dermatol* 58: 787-793.
27. Sutaria AH, Schlessinger J. *Acne Vulgaris* (2018) [Updated 2018 Nov 14]. In: StatPearls [Internet]. Treasure Island (FL).
28. Stoll S, Shalita AR, Webster GF, Kaplan R, Danesh S, et al. (2001) The effect of the menstrual cycle on acne. *J Am Acad Dermatol* 45: 957-960.
29. Geller L, Rosen J, Frankel A, Goldenberg G (2014) Perimenstrual flare of adult acne. *J Clin Aesthet Dermatol* 7: 30-34.
30. Elsaie ML (2016) Hormonal treatment of acne vulgaris: an update. *Clin Cosmet Investig Dermatol* 9: 241-248.
31. Zeichner JA, Baldwin HE, Cook-Bolden FE, Eichenfield LF, Fallon-Friedlander S, et al. (2017) Emerging Issues in Adult Female Acne. *J Clin Aesthet Dermatol* 10: 37-46.
32. Raghunath RS, Venables ZC, Millington GW (2015) The menstrual cycle and the skin. *Clin Exp Dermatol* 40: 111-115.
33. Sardana K, Sharma RC, Sarkar R (2002) Seasonal variation in acne vulgaris--myth or reality. *J Dermatol* 29: 484-488.
34. Tanghetti EA, Kawata AK, Daniels SR, Yeomans K, Burk CT, et al. (2014) Understanding the burden of adult female acne. *J Clin Aesthet Dermatol* 7: 22-30.
35. Zari S, Alrahmani D (2017) The association between stress and acne among female medical students in Jeddah, Saudi Arabia. *Clin Cosmet Investig Dermatol* 10: 503-506.
36. Bagatin E, Freitas THP, Machado MCR, Ribeiro BM, Nunes S, et al. (2019) Adult female acne: a guide to clinical practice. *An Bras Dermatol* 94: 62-75.
37. Bondade S, Hothota A, Basavaraju V (2019) Stressful life events and psychiatric comorbidity in acne-a case control study. *Asia Pac Psychiatry* 11: e12340.
38. Uhlhake E, Yentzer BA, Feldman SR (2010) Acne vulgaris and depression: a retrospective examination. *J Cosmet Dermatol* 9: 59-63.
39. Özçelik S, Kulaç İ, Yazıcı M, Öcal E (2018) Distribution of childhood skin diseases according to age and gender, a single institution experience. *Turk Pediatri Ars* 53: 105-112.
40. Makrantonaki E, Ganceviciene R, Zouboulis C (2011) An update on the role of the sebaceous gland in the pathogenesis of acne. *Dermatoendocrinol*. 3: 41-49.
41. Iftikhar U, Choudhry N (2019) Serum levels of androgens in acne & their role in acne severity. *Pak J Med Sci*. 35: 146-150.
42. Hoover E, Krishnamurthy K (2019) Physiology, Sebaceous Glands. StatPearls [Internet].
43. Ottaviani M, Camera E, Picardo M (2010) Lipid mediators in acne.
44. Downing DT, Stewart ME, Wertz PW, Strauss JS (1986) Essential fatty acids and acne. *J Am Acad Dermatol*. 14: 221-5.
45. Jung JY, Kwon HH, Hong JS, Yoon JY, Park MS, et al. (2014) Effect of dietary supplementation with omega-3 fatty acid and gamma-linolenic acid on acne vulgaris: a randomised, double-blind, controlled trial. *Acta Derm Venereol* 94: 521-525.
46. Silva JR, Burger B, Kühl CMC, Candreva T, Mariah B. P. dos Anjos, et al. (2018) Wound Healing and Omega-6 Fatty Acids: From Inflammation to Repair. 2018: 1-17
47. Kartal D, Yildiz H, Ertas R, Borlu M, Utas S (2016) Association between isolated female acne and insulin resistance: a prospective study. *G Ital Dermatol Venereol* 151: 353-357.
48. Hwang YL, Lee MH, Oh HI, et al. (2018) Isoginkgetin Inhibits Insulin-Like Growth Factor-1-Induced Sebum Production in Cultured Human Sebocytes. *Ann Dermatol* 30:394-396.
49. Picardo M, Ottaviani M, Camera E, Kim HJ, Lim CA, et al. (2009) Sebaceous gland lipids. *Dermatoendocrinol* 1: 68-71.
50. Tolaymat L, Zito PM (2019) *Adapalene* Stat Pearls Publishing.
51. Eady EA, Layton AM, Cove JH (2013) A honey trap for the treatment of acne: manipulating the follicular microenvironment to control *Propionibacterium acnes*. *Biomed Res Int*.
52. Pelle E, McCarthy J, Seltmann H, et al. (2008) Identification of histamine receptors and reduction of squalene levels by an antihistamine in sebocytes. *J Invest Dermatol* 128: 1280-5.
53. Seo YJ, Li ZJ, Choi DK, et al. (2014) Regional difference in sebum production by androgen susceptibility in human facial skin. *Exp Dermatol* 23: 70-72.
54. Ozuguz P, Dogruk Kacar S, Ekiz O, et al. (2014) Evaluation of serum vitamins A and E and zinc levels according to the severity of acne vulgaris. *Cutan Ocul Toxicol* 33: 99-102.
55. Vongraviopap S, Asawanonda P (2016) Dark chocolate exacerbates acne. *Int J Dermatol*. 55: 587-91.
56. Minh PPT, Bich DD, Hai VNT, Van TN, Cam VT, et al. (2019) Microneedling Therapy for Atrophic Acne Scar: Effectiveness and Safety in Vietnamese Patients. *Open Access Maced J Med Sci* 7: 293-297.
57. Tasoula E, Gregoriou S, Chalikias J, Lazarou D, Danopoulou I, et al. (2012) Rigopoulos D. The impact of acne vulgaris on quality of life and psychic health in young adolescents in Greece. Results of a population survey. *An Bras Dermatol* 87: 862-829.
58. Gollnick HP, Zouboulis CC (2014) Not all acne is acne vulgaris. *Dtsch Arztebl Int* 111: 301-12.
59. Taylor M, Gonzalez M, Porter R (2011) Pathways to inflammation: acne pathophysiology. *Eur J Dermatol* 21: 323-333.
60. Purdy S, de Berker D (2006) Acne. *BMJ* 333: 949-953.
61. Goodman G (2009) Cleansing and moisturizing in acne patients. *Am J Clin Dermatol Suppl* 1: 1-6.
62. Sparavigna A, Tenconi B, De Ponti I, La Penna L (2015) An innovative approach to the topical treatment of acne. *Clin Cosmet Investig Dermatol* 8: 179-185.
63. Purdy S, de Berker D (2011) Acne vulgaris. *BMJ Clin Evid* 1714.
64. Purdy S, Langston J, Tait L (2003) Presentation and management of acne in primary care: a retrospective cohort study. *Br J Gen Pract* 53: 525-529.
65. Costa CS, Bagatin E, Martimbianco ALC, da Silva EM, et al. (2018) Oral isotretinoin for acne. *Cochrane Database Syst Rev* 11: CD009435.
66. Ettl DL, Lamanno LR, Neyra SA, Ettl WJ, Ettl GL III, et al. (2017) Teens and Technology Transforming Acne Treatment. *Perm J* 21: 16-192.
67. Snast I, Dalal A, Twig G, Astman N, Kedem R, et al. (2019) Acne and Obesity: A Nationwide Study of 600,404 Adolescents. *J Am Acad Dermatol*. pii: S0190-9622: 30589-30594.
68. Halvorsen JA, Vleugels RA, Bjertness E, Lien L (2012) A population-based study of acne and body mass index in adolescents. *Arch Dermatol*. 148: 131-132.
69. Stewart TJ, Bazergy C (2018) Hormonal and dietary factors in acne vulgaris versus controls. *Dermatoendocrinol*. 22: e1442160.
70. Melnik B (2012) Dietary intervention in acne: Attenuation of increased mTORC1 signaling promoted by Western diet. *Dermatoendocrinol*. 4: 20-32.
71. Wang YY, Li SW, Luo S, Qin L, Zeng X, et al. (2019) How to Evaluate Acne in Reproductive-Age Women: An Epidemiological Study in Chinese Communities. *Biomed Res Int* 6126808.
72. Acne During Pregnancy. Available From: <https://www.webmd.com/skin-problems-and-treatments/acne/acne-during-pregnancy-treatments-causes#1>

73. Perera, Peiris, Pathmanathan D, Mallawaarachchi S, Karunathilake IM (2018) Relationship between acne vulgaris and cosmetic usage in Sri Lankan urban adolescent females. *J Cosmet Dermatol* 17: 431-436.
74. Taylor KW, Baird DD, Herring AH, Engel LS, Nichols HB, et al. (2017) Associations among personal care product use patterns and exogenous hormone use in the NIEHS Sister Study. *J Expo Sci Environ Epidemiol* 27: 458-464.
75. Nair PA, Salazar FJ. Acneiform Eruptions. [Updated 2018 Dec 2]. In: StatPearls [Internet]. Treasure Island (FL): StatPearls Publishing; 2019 Jan-. Available from: <https://www.ncbi.nlm.nih.gov/books/NBK459207/>
76. Bhate K, Williams HC (2013) Epidemiology of acne vulgaris. *Br J Dermatol* 168: 474-85.
77. George RM, Sridharan R (2018) Factors Aggravating or Precipitating Acne in Indian Adults: A Hospital-Based Study of 110 Cases. *Indian J Dermatol* 63: 328-331.
78. Huang X, Zhang J, Li J, Zhao S, Xiao Y, et al. (2019) Daily Intake of Soft Drinks and Moderate-to-Severe Acne Vulgaris in Chinese Adolescents. *J Pediatr* 204: 256-262.e3.
79. Goodman G. (2006) Acne--natural history, facts and myths. *Aust Fam Physician* 35: 613-6.
80. Chalyk N, Klochkov V, Sommereux L, et al. (2018) Continuous Dark Chocolate Consumption Affects Human Facial Skin Surface by Stimulating Corneocyte Desquamation and Promoting Bacterial Colonization. *J Clin Aesthet Dermatol* 11: 37-41.
81. Web George Mateljan Foundation. Shrimp What's New and Beneficial About Shrimp. Available From: <http://www.whfoods.com/genpage.php?friendly=1&tname=foodspice&dbid=107>
82. Kidson W (1998) Polycystic ovary syndrome: a new direction in treatment. *Med J Aust* 169: 537-40.
83. Aizawa H, Niimura M (1995) Elevated serum insulin-like growth factor-1 (IGF-1) levels in women with postadolescent acne. *J Dermatol* 22: 249-52.
84. Mahmood NF, Shipman AR (2016) The age-old problem of acne. *Int J Womens Dermatol* 3: 71-76.
85. Rössner S, John Harvey Kellogg (2006) Masturbation results in general debility, unnatural pale eyes and forehead acne. *Obes Rev* 7: 227-228.
86. Ayer J, Burrows N (2006) Acne: more than skin deep. *Postgrad Med J* 82: 500-506.
87. Misery L, Wolkenstein P, Amici JM, et al. (2015) Consequences of acne on stress, fatigue, sleep disorders and sexual activity: a population-based study. *Acta Derm Venereol* 95: 485-488.
88. Zelikson AS, Strauss JS, Mottaz J (1985) Ultrastructural changes in open comedones following treatment of cystic acne with isotretinoin. *Am J Dermatopathol* 7: 241-244.
89. InformedHealth.org (2013) Cologne, Germany: Institute for Quality and Efficiency in Health Care (IQWiG), Which birth control pills can help reduce acne?, [<https://www.ncbi.nlm.nih.gov/books/NBK279209/>]. Accessed on 2016 Jul 28.
90. Allen HB, LoPresti PJ (1980) Acne vulgaris aggravated by sunlight. *Cutis* 26: 254-256.
91. Padilha-Gonçalves A, Alvimar Ferreira J 1977 [Solar acne]. *Med Cutan Ibero Lat Am* 5: 271-274.
92. Magin P, Pond D, Smith W, et al. (2005) A systematic review of the evidence for 'myths and misconceptions' in acne management: diet, face-washing and sunlight. *Fam Pract* 22: 62-70.
93. Melnik BC, Schmitz G (2009) Role of insulin, insulin-like growth factor-1, hyperglycaemic food and milk consumption in the pathogenesis of acne vulgaris. *Exp Dermatol* 18: 833-841.
94. Cong TX, Hao D, Wen X, Li XH, He G, et al. (2019) From pathogenesis of acne vulgaris to anti-acne agents. *Arch Dermatol Res* 311: 337-349.
95. Dréno B (2017) What is new in the pathophysiology of acne, an overview. *J Eur Acad Dermatol Venereol* 31 Suppl 5: 8-12.
96. Alexeyev OA, Dekio I, Layton AM, Li H, Hughes H, et al. (2018) Why we continue to use the name *Propionibacterium acnes*. *Br J Dermatol* 179: 1227.
97. Bergfeld WF (2004) The pathophysiology of acne vulgaris in children and adolescents, Part 1. *Cutis* 74: 92-97.
98. Jiang H, Li C (2019) Common Pathogenesis of Acne Vulgaris and Atherosclerosis. *Inflammation* 42: 1-5.
99. Hanamatsu H, Ohnishi S, Sakai S, Yuyama K, Mitsutake S, et al. (2014) Altered levels of serum sphingomyelin and ceramide containing distinct acyl chains in young obese adults. *Nutr Diabetes* 4: e141.
100. Futerman AH, Hannun YA (2004) The complex life of simple sphingolipids. *EMBO Rep* 5: 777-782.
101. Borodzicz S, Rudnicka L, Mirowska-Guzel D, Cudnoch-Jedrzejewska A (2016) The role of epidermal sphingolipids in dermatologic diseases. *Lipids Health Dis* 15: 13.
102. Kaya S, Aslan İ, Kırac E, Karaarslan T, Aslan M (2019) *Propionibacterium acnes*-induced immunopathology correlates with health and disease association. *JCI Insight* 4: pii: 124687.
103. Webster GF (2005) The pathophysiology of acne. *Cutis* 76: 4-7.
104. Knor T (2005) The pathogenesis of acne. *Acta Dermatovenerol Croat* 13: 44-49.
105. Coyner T (2018) Insights Into the Management of Acne Vulgaris: Clinical Considerations for Acne Treatment. *Journal of the Dermatology Nurses' Association*: 10.
106. Castillo DE, Keri JE (2018) Chemical peels in the treatment of acne: patient selection and perspectives. *Clin Cosmet Investig Dermatol* 11: 365-372.
107. Li C, Chen J, Wang W, Ai M, Zhang Q, Kuang L (2019) Use of isotretinoin and risk of depression in patients with acne: a systematic review and meta-analysis. *BMJ Open* 9: e021549.
108. Tassavor M, Payette MJ (2019) Estimated cost efficacy of U.S. Food and Drug Administration-approved treatments for acne. *Dermatol Ther* 32: e12765.
109. Xiao Y, Chen L, Jing D, Deng Y, Chen X, et al. (2019) Willingness-to-pay and benefit-cost analysis of chemical peels for acne treatment in China. *Patient Prefer Adherence* 13: 363-370.
110. Zhang M, Silverberg JI, Kaffenberger BH (2017) Prescription patterns and costs of acne/rosacea medications in Medicare patients vary by prescriber specialty. *J Am Acad Dermatol* 77: 448-455.
111. Czilli T, Tan J, Knezevic S, Peters C (2016) Cost of Medications Recommended by Canadian Acne Clinical Practice Guidelines. *J Cutan Med Surg* 20: 542-545.
112. Saadawi AN, Esawy AM, Kandeel AH, El-Sayed W (2019) Microneedling by dermapen and glycolic acid peel for the treatment of acne scars: Comparative study. *J Cosmet Dermatol* 18: 107-114.
113. Kraft J, Freiman A (2011) Management of acne. *CMAJ* 183: E430-E435.
114. Titus S, Hodge J (2012) Diagnosis and treatment of acne. *Am Fam Physician* 86: 734-740.
115. Sun KL, Chang JM (2017) Special types of folliculitis which should be differentiated from acne. *Dermatoendocrinol* 9: e1356519.
116. Nair PA, Salazar FJ. Acneiform Eruptions. [Updated 2018 Dec 2]. In: StatPearls [Internet]. Treasure Island (FL): StatPearls Publishing; 2019 Jan-. Available from: <https://www.ncbi.nlm.nih.gov/books/NBK459207/>
117. Du-Thanh A, Kluger N, Bensalleh H, Guillot B (2011) Drug-induced acneiform eruption. *Am J Clin Dermatol* 12: 233-245.
118. Kazandjieva J, Tsankov N (2017) Drug-induced acne. *Clin Dermatol* 35: 156-162.
119. Pontello R, Kondo RN (2013) Drug-induced acne and rose pearl: similarities. *An Bras Dermatol* 88: 1039-1040.

120. Ballard K, Shuman VL. Hidradenitis Suppurativa. [Updated 2019 Feb 28]. In: StatPearls [Internet]. Treasure Island (FL): StatPearls Publishing; 2019 Jan-. Available from: <https://www.ncbi.nlm.nih.gov/books/NBK534867/>
121. Pink A, Anzengruber F, Navarini AA (2018) Acne and hidradenitis suppurativa. *Br J Dermatol* 178: 619-631.
122. Guerra KC, Krishnamurthy K. Miliaria. [Updated 2018 Dec 26]. In: StatPearls [Internet]. Treasure Island (FL): StatPearls Publishing; 2019 Jan-. Available from: <https://www.ncbi.nlm.nih.gov/books/NBK537176/>
123. Adotama P, Tinker D, Mitchell K, Glass DA, Allen P (2017) Barber Knowledge and Recommendations Regarding Pseudofolliculitis Barbae and Acne Keloidalis Nuchae in an Urban Setting. *JAMA Dermatol* 153: 1325-1326.
124. Tan AU, Schlosser BJ, Paller AS (2017) A review of diagnosis and treatment of acne in adult female patients. *Int J Womens Dermatol* 4: 56-71.
125. Tolaymat L, Hall MR. Dermatitis, Perioral (2018) In: StatPearls [Internet]. Treasure Island (FL): StatPearls Publishing.
126. Bikowski J (2009) Facial seborrheic dermatitis: a report on current status and therapeutic horizons. *J Drugs Dermatol*. 8: 125-133.
127. Dréno B, Bissonnette R, Gagné-Henley A, Barankin B, Lynde C, et al. (2018) Prevention and Reduction of Atrophic Acne Scars with Adapalene 0.3% Benzoyl Peroxide 2.5% Gel in Subjects with Moderate or Severe Facial Acne: Results of a 6-Month Randomized, Vehicle-Controlled Trial Using Intra-Individual Comparison. *Am J Clin Dermatol*. Pp:275-286.
128. Connolly D, Vu HL, Mariwalla K, et al. (2017) Acne Scarring-Pathogenesis, Evaluation, and Treatment Options. *J Clin Aesthet Dermatol*. 10: 12-23.
129. Fabbrocini G, Annunziata MC, D'Arco V, et al. (2010) Acne scars: pathogenesis, classification and treatment. *Dermatol Res Pract*.
130. Fife D (2011) Practical evaluation and management of atrophic acne scars: tips for the general dermatologist. *J Clin Aesthet Dermatol*. 4: 50-57.
131. Kravvas G, Al-Niaimi F (2017) A systematic review of treatments for acne scarring. Part 1: Non-energy-based techniques. *Scars Burn Heal*.
132. Gan SD, Graber EM (2015) Papular scars: an addition to the acne scar classification scheme. *J Clin Aesthet Dermatol*. 8: 19-20.
133. McGinty S, Siddiqui WJ (2019) Keloid. StatPearls [Internet].
134. Vilar GN, Santos LA, Sobral Filho JF (2015) Quality of life, self-esteem and psychosocial factors in adolescents with acne vulgaris. *An Bras Dermatol*. 90: 622-629.
135. Dreno B, Bagatin E, Blume-Peytavi U, et al. (2018) Female type of adult acne: Physiological and psychological considerations and management. *J Dtsch Dermatol Ges*. 16: 1185-1194.
136. Hazarika N, Archana M (2016) The Psychosocial Impact of Acne Vulgaris. *Indian J Dermatol*. 61: 515-20.
137. Behnam B, Taheri R, Ghorbani R, Allameh P (2013) Psychological impairments in the patients with acne. *Indian J Dermatol*. 58: 26-29.
138. Alanazi MS, Hammad SM, Mohamed AE (2018) Prevalence and psychological impact of Acne vulgaris among female secondary school students in Arar city, Saudi Arabia, in 2018. *Electron Physician*. 10: 7224-7229.
139. Gao Y, Wei EK, Arron ST, et al. (2017) Acne, sexual orientation, and mental health among young adults in the United States: A population-based, cross-sectional study. *J Am Acad Dermatol*. 77: 971-973.
140. Kurek A, Peters EM, Chanwangpong A, et al. (2012) Profound disturbances of sexual health in patients with acne inversa. *J Am Acad Dermatol*. 67: 422-428.
141. Bray AP, Kravvas G, Skevington SM, et al. (2019) Is there an association between isotretinoin therapy and adverse mood changes? A prospective study in a cohort of acne patients. *J Dermatolog Treat*. 18: 1-6.
142. Hull PR, D'Arcy C. (2015) Acne, depression, and suicide. *Dermatol Clin*. 23: 665-74.
143. Fox L, Csongradi C, Aucamp M, du Plessis J, Gerber M (2016) Treatment Modalities for Acne. *Molecules* 21: 1063.
144. Ulvestad M, Bjertness E, Dalgard F, Halvorsen JA. (2017) Acne and dairy products in adolescence: results from a Norwegian longitudinal study. *J Eur Acad Dermatol Venereol*. 530-535.
145. Aghasi M, Golzarand M, Shab-Bidar S, Aminianfar A, Omidian M, Taheri F. (2018) Dairy intake and acne development: A meta-analysis of observational studies. *Clin Nutr*.
146. Delost GR, Delost ME, Lloyd J. (2016) The impact of chocolate consumption on acne vulgaris in college students: A randomized crossover study. *J Am Acad Dermatol*. 220-222.
147. Smith RN, Mann NJ, Braue A, Mäkeläinen H, Varigos GA. (2007) A low-glycemic-load diet improves symptoms in acne vulgaris patients: a randomized controlled trial. *Am J Clin Nutr*. pp:107-15.
148. Burriss J, Shikany JM, Rietkerk W, Woolf K. (2018) A Low Glycemic Index and Glycemic Load Diet Decreases Insulin-like Growth Factor-1 among Adults with Moderate and Severe Acne: A Short-Duration, 2-Week Randomized Controlled Trial. *J Acad Nutr Diet*. 1874-1885.
149. Bove A, Hebreo J, Wylie-Rosett J, Isasi CR. (2006) Burger King and Subway: key nutrients, glycemic index, and glycemic load of nutritionally promoted items. *Diabetes Educ*. 675-690.
150. Cordain L, Lindeberg S, Hurtado M, Hill K, Eaton SB, (2002) Brand-Miller J. Acne vulgaris: a disease of Western civilization. *Arch Dermatol*. 1584-1590.
151. Klepchukova A. (2019) Acne: Everything You Need to Know. Flo Health, Inc.
152. National Research Council (US) (1989) Committee on Diet and Health. Diet and Health: Implications for Reducing Chronic Disease Risk. Washington (DC): National Academies Press (US) Dietary Fiber. Available.
153. Bowe WP, Logan AC. (2011) Acne vulgaris, probiotics and the gut-brain-skin axis - back to the future? *Gut Pathog*.
154. Zhang H, Liao W, Chao W, Chen Q, Zeng H, et al. (2008) Risk factors for sebaceous gland diseases and their relationship to gastrointestinal dysfunction in Han adolescents. *J Dermatol*. 555-561.
155. Saric S, Notay M, Sivamani RK. (2016) Green Tea and Other Tea Polyphenols: Effects on Sebum Production and Acne Vulgaris. *Antioxidants* (Basel).
156. Database of Abstracts of Reviews of Effects (DARE) (2014): Quality-assessed Reviews [Internet]. York (UK) Centre for Reviews and Dissemination (UK) Polyphenols as novel treatment options for dermatological diseases: a systematic review of clinical trials.
157. Mahmood T, Akhtar N, Moldovan C (2013) A comparison of the effects of topical green tea and lotus on facial sebum control in healthy humans. *Hippokratia*. 64-67.
158. Lee KE, Youm JK, Lee WJ, Kang S, Kim YJ. (2017) Polyphenol-rich apple extract inhibits dexamethasone-induced sebaceous lipids production by regulating SREBP1 expression. *Exp Dermatol*. Lee KE, Youm JK, Lee WJ, Kang S, Kim YJ. (2017) Polyphenol-rich apple extract inhibits dexamethasone-induced sebaceous lipids production by regulating SREBP1 expression. *Exp Dermatol*.
159. El-Akawi Z, Abdel-Latif N, Abdul-Razzak K. (2006) Does the plasma level of vitamins A and E affect acne condition? *Clin Exp Dermatol*. Pp:430-434.
160. Stringer T, Nagler A, Orlow SJ, Oza VS. (2018) Clinical evidence for washing and cleansers in acne vulgaris: a systematic review. *J Dermatolog Treat*. pp:688-693.
161. Choi YS, Suh HS, Yoon MY, Min SU, Kim JS, et al. (2010) A study of the efficacy of cleansers for acne vulgaris. *J Dermatolog Treat*. Pp:201-205.

162. Draelos ZD (2006) The effect of a daily facial cleanser for normal to oily skin on the skin barrier of subjects with acne. *Cutis*.Pp:34-40.
163. Prakash C, Bhargava P, Tiwari S, Majumdar B, Bhargava RK (2017) Skin Surface pH in Acne Vulgaris: Insights from an Observational Study and Review of the Literature. *J Clin Aesthet Dermatol*. Pp:33-39.
164. Albuquerque RG, Rocha MA, Bagatin E, Tufik S, Andersen ML (2014) Could adult female acne be associated with modern life? *Arch Dermatol Res* 306: 683-688.
165. Chatzikonstantinou F, Miskedaki A, Antoniou C, Chatzikonstantinou M, Chrousos G, et al. (2019) A novel cognitive stress management technique for acne vulgaris: a short report of a pilot experimental study. *Int J Dermatol* 58: 218-220.
166. Jović A, Marinović B, Kostović K, Čeović R, Basta-Juzbašić A, et al. (2017) The Impact of Psychological Stress on Acne. *Acta Dermatovenerol Croat* 25: 1133-1141.
167. Capitano B, Sinagra JL, Ottaviani M, et al. (2009) Acne and smoking. *Dermatoendocrinol*. 1: 129-35.
168. Yang YS, Lim HK, Hong KK, Shin MK, Lee JW, et al. (2014) Cigarette smoke-induced interleukin-1 alpha may be involved in the pathogenesis of adult acne. *Ann Dermatol* 26: 11-16.
169. Mohtady O (2018) How Your Skin Changes When Your Smoke. Digital Therapeutics, Inc, SEPTEMBER 26, 2018. <https://www.quitgenius.com/blog/how-your-skin-changes-when-your-smoke>.
170. What is the Role of Benzoyl Peroxide Cleansers in Acne Management? (2008):Do they Decrease Propionibacterium acnes Counts? Do they Reduce Acne Lesions? *J Clin Aesthet Dermatol*. pp:48-51.
171. Kawashima M, Nagare T, Doi M (2017) Clinical efficacy and safety of benzoyl peroxide for acne vulgaris: Comparison between Japanese and Western patients. *J Dermatol*.
172. SAGRANSKY M, YENTZER BA, FELDMAN SR (2009) Benzoyl peroxide: a review of its current use in the treatment of acne vulgaris. *Expert Opin Pharmacother* 2555-2562.
173. Kircik LH (2013) The role of benzoyl peroxide in the new treatment paradigm for acne. *J Drugs Dermatol* pp:73-76.
174. Matin T, Goodman MB (2019) Benzoyl Peroxide. Treasure Island (FL): StatPearls.
175. Fakhouri T, Yentzer BA, Feldman SR. (2009) Advancement in benzoyl peroxide-based acne treatment: methods to increase both efficacy and tolerability. *J Drugs Dermatol*. pp:657-661.
176. Stein Gold L, Baldwin HE, Lin T (2017) Management of Severe Acne Vulgaris With Topical Therapy. *J Drugs Dermatol*. pp: 1134-1138.
177. Gold MH, Baldwin H, Lin T (2018) Management of comedonal acne vulgaris with fixed-combination topical therapy. *J Cosmet Dermatol*. Pp:227-231.
178. Mansu S, Liang H, Parker S, Coyle ME, Wang K, et al. (2018) Acupuncture for Acne Vulgaris: A Systematic Review and Meta-Analysis. *Evid Based Complement Alternat Med*.
179. Leyden JJ, Del Rosso JQ (2012) The effect of benzoyl peroxide 9.8% emollient foam on reduction of Propionibacterium acnes on the back using a short contact therapy approach. *J Drugs Dermatol*. Pp:830-833.
180. Kong YL, Tey HL (2013) Treatment of acne vulgaris during pregnancy and lactation. *Drugs*. Pp:779-787.
181. Dréno B, Layton A, Zouboulis CC, López-Esteban JL, Zalewska-Janowska A, et al. (2013) Adult female acne: a new paradigm. *J Eur Acad Dermatol Venereol*. Pp:1063-170.
182. Aoki S, Nakase K, Hayashi N, Noguchi N. (2019) Transconjugation of erm(X) conferring high-level resistance of clindamycin for Cutibacterium acnes. *J Med Microbiol*. Pp:26-30.
183. Murphy PB, Le JK, Clindamycin (2019) In: StatPearls [Internet]. Treasure Island (FL): StatPearls Publishing.
184. Ohlson J, Dakovic R, Berg M. (2019) Observational Study of Clindamycin Phosphate and Tretinoin Gel for the Treatment of Acne. *J Drugs Dermatol*. pp:328-334.
185. Del Rosso JQ. (2015) Clindamycin Phosphate 1.2% Tretinoin 0.025% Gel for the Treatment of Acne Vulgaris: Which Patients are Most Likely to Benefit the Most? *J Clin Aesthet Dermatol*. Pp:19-23.
186. Ochsendorf F. (2015) Clindamycin phosphate 1.2% tretinoin 0.025%: a novel fixed-dose combination treatment for acne vulgaris. *J Eur Acad Dermatol Venereol*. Pp:8-13.
187. Murray J, Potts A. (2014) The phototoxic and photoallergy potential of clindamycin phosphate 1.2% tretinoin 0.025% gel for facial acne: results of two single-center, evaluator-blinded, randomized, vehicle-controlled phase 1 studies in healthy volunteers. *J Drugs Dermatol*. Pp:16-22.
188. Amar L, Kircik LH. (2018) Treatment of Moderate Acne Vulgaris in Fitzpatrick Skin Type V or VI: Efficacy and Tolerability of Fixed Combination Clindamycin Phosphate 1.2% Benzoyl Peroxide 3.75% Gel. *J Drugs Dermatol*. Pp:1107-1112.
189. Zaenglein AL, Shamban A, Webster G, Del Rosso J, Dover JS, Swinyer L, Stein L, Lin X, Draelos Z, Gold M, Thiboutot D. (2013) A phase IV, open-label study evaluating the use of triple-combination therapy with minocycline HCl extended-release tablets, a topical antibiotic/retinoid preparation and benzoyl peroxide in patients with moderate to severe acne vulgaris. *J Drugs Dermatol*. Pp:619-25.
190. Zeichner JA, Wong V, Linkner RV, (2013) Haddican M. Efficacy and safety of tretinoin 0.025%/clindamycin phosphate 1.2% gel in combination with benzoyl peroxide 6% cleansing cloths for the treatment of facial acne vulgaris. *J Drugs Dermatol*. Pp:277-82.
191. Leyden J, Stein-Gold L, Weiss J. (2017) Why Topical Retinoids Are Mainstay of Therapy for Acne. *Dermatol Ther (Heidelb)*. Pp:293-304.
192. Thielitz A, Gollnick H. (2008) Topical retinoids in acne vulgaris: update on efficacy and safety. *Am J Clin Dermatol*.pp:369-81.
193. Kolli SS, Pecone D, Pona A, Cline A, Feldman SR. (2019) Topical Retinoids in Acne Vulgaris: A Systematic Review. *Am J Clin Dermatol*. pp:345-65.
194. Kircik LH (2011) Synergy and its clinical relevance in topical acne therapy. *J Clin Aesthet Dermatol* 4: 30-33.
195. Tan J, Tanghetti E, Baldwin H, Stein Gold L, Lain E. (2019) The Role of Topical Retinoids in Prevention and Treatment of Atrophic Acne Scarring: Understanding the Importance of Early Effective Treatment. *J Drugs Dermatol*. Pp:255-260.
196. Jain S. (2004) Topical tretinoin or adapalene in acne vulgaris: an overview. *J Dermatolog Treat*.pp:200-207.
197. Chandrashekhar BS, Anitha M, Ruparelia M, Vaidya P, Aamir R, Shah S, Thilak S, Aurangabadkar S, Pal S, Saraswat A, Sanmukhani JJ. (2015) Tretinoin Nanogel 0.025% Versus Conventional Gel 0.025% in Patients with Acne Vulgaris: A Randomized, Active Controlled, Multicentre, Parallel Group, Phase IV Clinical Trial.
198. Harper JC, Roberts WE, Zeichner JA, Guenin E, Bhatt V, et al. (2019) Novel tretinoin 0.05% lotion for the once-daily treatment of moderate-to-severe acne vulgaris: assessment of safety and tolerability in subgroups. *J Dermatolog Treat* 2: 1-8.
199. Hajheydari Z, Saeedi M, Morteza-Semnani K, Soltani A (2014) Effect of Aloe vera topical gel combined with tretinoin in treatment of mild and moderate acne vulgaris: a randomized, double-blind, prospective trial. *J Dermatolog Treat* 25: 123-129.
200. Deshmukh SN, Badar VA, Mahajan MM, Dudhgaonkar DS, Mishra D (2018) Comparison of efficacy and safety of topical 1% nadifloxacin and tretinoin 0.025% combination therapy with 1% clindamycin and tretinoin 0.025% combination therapy in patients of mild-to-moderate acne. *Perspect Clin Res* 9: 161-164.
201. Praderio C (2017) Here's how 13 celebrities got rid of their acne. *INSIDER (Health)*.
202. Khayef G, Young J, Burns-Whitmore B, et al. (2012) Effects of fish oil supplementation on inflammatory acne. *Lipids Health Dis*. 11: 165. Khayef G, Young J, Burns-Whitmore B, et al. (2012) Effects of fish oil

- supplementation on inflammatory acne. *Lipids Health Dis*. 11: 165.
203. Orenstein H. How 32 Celebrities With Acne Handle Blemishes and Breakouts. SEVENTEEN, 2018.
204. Gabros S, Zito PM (2019) Topical Corticosteroids. StatPearls [Internet].
205. Yasir M, Sonthalia S (2019) Corticosteroid Adverse Effects. StatPearls [Internet].
206. Cleaning Makeup Brushes Like A Pro. Available From: <https://kjbennett.com/category/beauty-tutorial/>.
207. Burchacka E, Potaczek P, Padaszyński P, Karłowicz-Bodalska K, Han T, et al. (2016) New effective azelaic acid liposomal gel formulation of enhanced pharmaceutical bioavailability. *Biomed Pharmacother* 83: 771-775.
208. Hashim PW, Chen T, Harper JC, Kircik LH (2018) The Efficacy and Safety of Azelaic Acid 15% Foam in the Treatment of Facial Acne Vulgaris. *J Drugs Dermatol* 17: 641-645.
209. Kainz JT, Berghammer G, Auer-Grumbach P, Lackner V, Perl-Convalexius S, et al. (2016) Azelaic acid 20 % cream: effects on quality of life and disease severity in adult female acne patients. *J Dtsch Dermatol Ges* 14: 1249-1259.
210. Apriani EF, Rosana Y, Iskandarsyah I (2019) Formulation, characterization, and in vitro testing of azelaic acid ethosome-based cream against *Propionibacterium* acnes for the treatment of acne. *J Adv Pharm Technol Res* 10: 75-80.
211. Abdel Hay R, Hegazy R, Abdel Hady M, Saleh N (2019) Clinical and dermoscopic evaluation of combined (salicylic acid 20% and azelaic acid 20%) versus trichloroacetic acid 25% chemical peel in acne: an RCT. *J Dermatolog Treat* 1: 1-6.
212. Rocha M, Sanudo A, Bagatin E (2017) The effect on acne quality of life of topical azelaic acid 15% gel versus a combined oral contraceptive in adult female acne: A randomized trial. *Dermatoendocrinol* 9: e1361572.
213. Stein Gold LF, Jarratt MT, Bucko AD, Grekin SK, Berlin JM, et al. (2016) Efficacy and Safety of Once-Daily Dapsone Gel, 7.5% for Treatment of Adolescents and Adults with Acne Vulgaris: First of Two Identically Designed, Large, Multicenter, Randomized, Vehicle-controlled Trials. *J Drugs Dermatol* 15: 553-561.
214. Thiboutot DM, Kircik L, McMichael A, Cook-Bolden FE, Tyring SK, et al. (2016) Efficacy, Safety, and Dermal Tolerability of Dapsone Gel, 7.5% in Patients with Moderate Acne Vulgaris: A Pooled Analysis of Two Phase 3 Trials. *J Clin Aesthet Dermatol* 9: 18-27.
215. Eichenfield LF, Lain T, Frankel EH, Jones TM, Chang-Lin JE, et al. (2016) Efficacy and Safety of Once-Daily Dapsone Gel, 7.5% for Treatment of Adolescents and Adults With Acne Vulgaris: Second of Two Identically Designed, Large, Multicenter, Randomized, Vehicle-Controlled Trials. *J Drugs Dermatol* 15: 962-969.
216. Jarratt MT, Jones TM, Chang-Lin JE, Tong W, Berk DR, et al. (2016) Safety and Pharmacokinetics of Once-Daily Dapsone Gel, 7.5% in Patients With Moderate Acne Vulgaris. *J Drugs Dermatol* 15: 1250-1259.
217. Al-Salama ZT, Deeks ED (2017) Dapsone 7.5% Gel: A Review in Acne Vulgaris. *Am J Clin Dermatol* 18: 139-145.
218. Alexis AF, Burgess C, Callender VD, Herzog JL, Roberts WE, et al. (2016) The Efficacy and Safety of Topical Dapsone Gel, 5% for the Treatment of Acne Vulgaris in Adult Females with Skin of Color. *J Drugs Dermatol* 15: 197-204.
219. Taylor SC, Cook-Bolden FE, McMichael A, Downie JB, Rodriguez DA, et al. (2018) Efficacy, Safety, and Tolerability of Topical Dapsone Gel, 7.5% for Treatment of Acne Vulgaris by Fitzpatrick Skin Phototype. *J Drugs Dermatol* 17: 160-167.
220. Del Rosso JQ, Kircik L, Tangheiti E (2018) Management of Truncal Acne Vulgaris with Topical Dapsone 7.5% Gel. *J Clin Aesthet Dermatol* 11: 45-50.
221. Draelos ZD, Rodriguez DA, Kempers SE, Bruce S, Peredo MI, et al. (2017) Treatment Response With Once-Daily Topical Dapsone Gel, 7.5% for Acne Vulgaris: Subgroup Analysis of Pooled Data from Two Randomized, Double-Blind Stu. *J Drugs Dermatol* 16: 591-598.
222. Tangheiti E, Harper J, Baldwin H, Kircik L, Bai Z, et al. (2018) Once-Daily Topical Dapsone Gel, 7.5%: Effective for Acne Vulgaris Regardless of Baseline Lesion Count, With Superior Efficacy in Females. *J Drugs Dermatol* 17: 1192-1198.
223. Kircik LH (2016) Use of Dapsone 5% Gel as Maintenance Treatment of Acne Vulgaris Following Completion of Oral Doxycycline and Dapsone 5% Gel Combination Treatment. *J Drugs Dermatol* 15: 191-195.
224. Wohlrab J, Michael J (2018) Dapsone for topical use in extemporaneous preparations. *J Dtsch Dermatol Ges* 16: 34-40.
225. Subramaniam A, Corallo C, Nagappan R (2010) Dapsone-associated methaemoglobinaemia in patients with a haematologic malignancy. *Anaesth Intensive Care* 38: 1070-1076.
226. Molinelli E, Paolinelli M, Campanati A, Brisigotti V, Offidani A (2019) Metabolic, pharmacokinetic, and toxicological issues surrounding dapsone. *Expert Opin Drug Metab Toxicol* 15: 367-379.
227. El-Nabarawi MA, Shamma RN, Farouk F, Nasralla SM (2019) Bilosomes as a novel carrier for the cutaneous delivery for dapsone as a potential treatment of acne: Preparation, characterization and in-vivo skin deposition assay. *J Liposome Res* 22: 1-26.
228. Endly DC, Miller RA (2017) Oily Skin: A review of Treatment Options. *J Clin Aesthet Dermatol* 10: 49-55.
229. Bissonnette R, Poulin Y, Drew J, Hofland H, Tan J (2017) Olumacostat glasaretil, a novel topical sebum inhibitor, in the treatment of acne vulgaris: A phase IIa, multicenter, randomized, vehicle-controlled study. *J Am Acad Dermatol* 76: 33-39.
230. Melnik BC (2017) Olumacostat Glasaretil, a Promising Topical Sebum-Suppressing Agent that Affects All Major Pathogenic Factors of Acne Vulgaris. *J Invest Dermatol* 137: 1405-1408.
231. Afzali BM, Yaghoobi E, Yaghoobi R, Bagherani N, Dabbagh MA (2012) Comparison of the efficacy of 5% topical spironolactone gel and placebo in the treatment of mild and moderate acne vulgaris: a randomized controlled trial. *J Dermatolog Treat* 23: 21-25.
232. Charny JW, Choi JK, James WD (2017) Spironolactone for the treatment of acne in women, a retrospective study of 110 patients. *Int J Womens Dermatol* 3: 111-115.
233. Trifu V, Tiplica GS, Naumescu E, Zalupca L, Moro L, et al. (2011) Cortexolone 17 α -propionate 1% cream, a new potent antiandrogen for topical treatment of acne vulgaris. A pilot randomized, double-blind comparative study vs. placebo and tretinoin 0.05% cream. *Br J Dermatol* 165: 177-83.
234. Meingassner JG, Aschauer H, Winiski AP, Dales N, Yowe D, et al. (2013) Pharmacological inhibition of stearyl CoA desaturase in the skin induces atrophy of the sebaceous glands. *J Invest Dermatol* 133: 2091-2094.
235. Rubinchik E, Dugourd D, Algara T, Pasetka C, Friedland HD (2009) Antimicrobial and antifungal activities of a novel cationic antimicrobial peptide, omiganan, in experimental skin colonisation models. *Int J Antimicrob Agents* 34: 457-461.
236. Garner SE, Eady A, Bennett C, Newton JN, Thomas K, et al. (2012) Minocycline for acne vulgaris: efficacy and safety. *Cochrane Database Syst Rev* 8: CD002086.
237. Gold LS, Dhawan S, Weiss J, Draelos ZD, Ellman H, et al. (2019) A novel topical minocycline foam for the treatment of moderate-to-severe acne vulgaris: Results of 2 randomized, double-blind, phase 3 studies. *J Am Acad Dermatol* 80: 168-177.
238. Bonati LM, Dover JS (2019) Treating Acne With Topical Antibiotics: Current Obstacles and the Introduction of Topical Minocycline as a New Treatment Option. *J Drugs Dermatol* 18: 240-244.
239. Jones TM, Ellman H, deVries T (2017) Pharmacokinetic Comparison of Once-Daily Topical Minocycline Foam 4% vs Oral Minocycline for Moderate-to-Severe Acne. *J Drugs Dermatol* 16: 1022-1028.

240. Alexis A, Del Rosso JQ, Desai SR, Downie JB, Draelos ZD, et al. (2018) BPX-01 Minocycline Topical Gel Shows Promise for the Treatment of Moderate-to-severe Inflammatory Acne Vulgaris. *J Clin Aesthet Dermatol* 11: 25-35.
241. Jeong S, Hermsmeier M, Osseiran S, Yamamoto A, Nagavarapu U, et al. (2018) Visualization of drug distribution of a topical minocycline gel in human facial skin. *Biomed Opt Express* 9: 3434-3448.
242. Ustun I, Rifaioglu EN, Sen BB, Inam MU, Gokce C (2013) Gynecomastia: a rare complication of isotretinoin? *Cutan Ocul Toxicol* 32: 93-94.
243. Thomazini BF, Lamas CA, Dolder MAH (2018) Safety of isotretinoin treatment as measured by liver parameters. *Histol Histopathol* 17: 18075.
244. Oliveira JM, Sobreira G, Velosa J, Telles Correia D, Filipe P (2018) Association of Isotretinoin With Depression and Suicide: A Review of Current Literature. *J Cutan Med Surg* 22: 58-64.
245. Huang YC, Cheng YC (2017) Isotretinoin treatment for acne and risk of depression: A systematic review and meta-analysis. *J Am Acad Dermatol* 76 :1068-1076.
246. Botsali A, Kocyigit P, Uran P (2019) The Effects of Isotretinoin on Affective and Cognitive Functions are Disparate in Adolescent Acne Vulgaris Patients. *J Dermatolog Treat* 15: 1-17.
247. Charrow A, Xia FD, Lu J, Waul M, Joyce C, et al. (2019) Differences in isotretinoin start, interruption, and early termination across race and sex in the iPLEDGE era. *PLoS One* 14: e0210445.
248. Gómez-Flores M, Poletti-Vázquez DE, García-Hidalgo L, Fierro-Arias L, Herz-Ruelas M, et al. (2019) Second joint position paper: Use of isotretinoin in severe acne. *Rev Med Inst Mex Seguro Soc* 56: 441-446.
249. Soyuduru G, Ösoy Adısen E, Kadioğlu Özer İ, Aksal AB (2019) The effect of isotretinoin on insulin resistance and adipocytokine levels in acne vulgaris patients. *Turk J Med Sci* 49: 238-244.
250. Van TLT, Minh PN, Thuy PTT, Gandolfi M, Satolli F, et al. (2019) Efficacy of Oral Low-Dose Isotretinoin in the Treatment of Acne Vulgaris in Vietnam. *Open Access Maced J Med Sci* 7: 279-282.
251. Fouladgar N, Khabazkhoob M, Hanifnia AR, Yekta A, et al. (2018) Evaluation of the effects of isotretinoin for treatment of acne on corneal sensitivity. *J Curr Ophthalmol*. 30: 326-329.
252. Kim NR, Yoon SR, Choi JS, Ahn HK, Lee SY, et al. (2018) Isotretinoin exposure in pregnant women in Korea. *Obstet Gynecol Sci* 0061: 649-654.
253. Tasli H, Yurekli A, Gokgoz MC, Karakoc O (2018) Effects of oral isotretinoin therapy on the nasal cavities. *Braz J Otorhinolaryngol In Press*. Tasli H, Yurekli A, Gokgoz MC, Karakoc O (2018) Effects of oral iso-tretinoin therapy on the nasal cavities. *Braz J Otorhinolaryngol In Press*.
254. El Aziz Ragab MA, Omar SS, Collier A, El-Wafa RAHA, Goma N (2018) The effect of continuous high versus low dose oral iso-tretinoin regimens on dermcidin expression in patients with moderate to severe acne vulgaris. *Dermatol Ther* 31: e12715.
255. Nakano T, Yoshino T, Fujimura T, Arai S, Mukuno A, et al. (2015) Reduced expression of dermcidin, a peptide active against propionic bacterium acnes, in sweat of patients with acne vulgaris. *Acta Derm Venereol* 95: 783-786.
256. Drugs and Lactation Database (LactMed) [Internet] (2006) Acitretin: Bethesda (MD): National Library of Medicine (US). [Updated 1 Apr 2019].
257. Drugs and Lactation Database (LactMed) [Internet] (2006) Isotretinoin: Bethesda (MD): National Library of Medicine (US). [Updated 3 Dec 2018].
258. Khiali S, Gharekhani A, Entezari-Maleki T. Isotretinoin (2018) A review on the Utilization Pattern in Pregnancy. *Adv Pharm Bull* 8: 377-382.
259. Garthwaite SM, McMahon EG (2004) The evolution of aldosterone antagonists. *Mol Cell Endocrinol* 217: 27-31.
260. Grandhi R, Alikhan A (2017) Spironolactone for the Treatment of Acne: A 4-Year Retrospective Study. *Dermatology* 233: 141-144.
261. Layton AM, Eady EA, Whitehouse H, Del Rosso JQ, Fedorowicz Z, et al. (2017) Oral Spironolactone for Acne Vulgaris in Adult Females: A Hybrid Systematic Review. *Am J Clin Dermatol* 18: 169-191.
262. Rocha MA, Bagatin E (2018) Adult-onset acne: prevalence, impact, and management challenges. *Clin Cosmet Investig Dermatol* 11: 59-69.
263. Isvy-Joubert A, Nguyen JM, Gaultier A, Saint-Jean M, Le Moigne M, et al. (2017) Adult female acne treated with spironolactone: a retrospective data review of 70 cases. *Eur J Dermatol* 27: 393-398.
264. Barbieri JS, Choi JK, Mitra N, Margolis DJ (2018) Frequency of Treatment Switching for Spironolactone Compared to Oral Tetracycline-Class Antibiotics for Women with Acne: A Retrospective Cohort Study 2010-2016. *J Drugs Dermatol* 17: 632-638.
265. Amin K, Riddle CC, Aires DJ, Schweiger ES (2007) Common and alternate oral antibiotic therapies for acne vulgaris: a review. *J Drugs Dermatol* 6: 873-880.
266. Farrah G, Tan E (2016) The use of oral antibiotics in treating acne vulgaris: a new approach. *Dermatol Ther*. 29: 377-384.
267. Zaenglein AL, Pathy AL, Schlosser BJ, Alikhan A, Baldwin HE, et al. (2016) Guidelines of care for the management of acne vulgaris. *J Am Acad Dermatol* 74: 945-973.
268. Cross R, Ling C, Day NP, McGready R, Paris DH (2016) Revisiting doxycycline in pregnancy and early childhood--time to rebuild its reputation? *Expert Opin Drug Saf* 15: 367-382.
269. Muanda FT, Sheehy O, Bérard A (2017) Use of antibiotics during pregnancy and risk of spontaneous abortion. *CMAJ* 189: E625-E633.
270. Del Rosso JQ (2015) Oral Doxycycline in the Management of Acne Vulgaris: Current Perspectives on Clinical Use and Recent Findings with a New Double-scored Small Tablet Formulation. *J Clin Aesthet Dermatol* 8: 19-26.
271. Kim JE, Park AY, Lee SY, Park YL, Whang KU, et al. (2018) Comparison of the Efficacy of Azithromycin Versus Doxycycline in Acne Vulgaris: A Meta-Analysis of Randomized Controlled Trials. *Ann Dermatol*. 30: 417-426.
272. Kapadia N, Talib A (2004) Acne treated successfully with azithromycin. *Int J Dermatol* 43: 766-767.
273. Fernandez-Obregon AC (2000) Azithromycin for the treatment of acne. *Int J Dermatol* 39: 45-50.
274. Dhaher SA, Jasim ZM (2018) The adjunctive effect of desloratadine on the combined azithromycin and iso-tretinoin in the treatment of severe acne: Randomized clinical trial. *Journal of Dermatology and Dermatologic Surgery* 22: 21-25.
275. Nakase K, Sakuma Y, Nakaminami H, Noguchi N (2016) Emergence of fluoroquinolone-resistant *Propionibacterium acnes* caused by amino acid substitutions of DNA gyrase but not DNA topoisomerase IV. *Anaerobe* 42: 166-171.
276. Khodaeiani E, Fouladi RF, Yousefi N, Amirnia M, Babaeinejad S, et al. (2012) Efficacy of 2% metronidazole gel in moderate acne vulgaris. *Indian J Dermatol* 57: 279-281.
277. Awan SZ, Lu J (2017) Management of severe acne during pregnancy: A case report and review of the literature. *Int J Womens Dermatol* 3: 145-150.
278. Cooper DB, Adigun R, Bhimji SS (2019) Oral Contraceptive Pills. In: *StatPearls*, Treasure Island (FL): StatPearls Publishing.
279. Lemay A, Poulin Y (2002) Oral contraceptives as anti-androgenic treatment of acne. *J Obstet Gynaecol Can* 24: 559-567.
280. Nguyen HL, Tollefson MM (2017) Endocrine disorders and hormonal therapy for adolescent acne. *Curr Opin Pediatr* 29: 455-465.
281. Chan CS, Harting M, Rosen T (2009) Systemic and barrier contraceptives for the dermatologist: a review. *Int J Dermatol* 48: 795-814.
282. De Leo V, Musacchio MC, Cappelli V, Piomboni P, Morgante G (2016) Hormonal contraceptives: pharmacology tailored to women's health.

- Hum Reprod Update 22: 634-646.
283. Rocha MAD, Guadanhim LRS, Sanudo A, Bagatin E (2017) Modulation of Toll Like Receptor-2 on sebaceous gland by the treatment of adult female acne. *Dermato-endocrinol* 9: e1361570.
284. Coneac A, Muresan A, Orasan MS (2014) Anti-androgenic Therapy with Ciproterone Acetate in Female Patients Who Suffer from Both Androgenetic Alopecia and Acne Vulgaris. *Clujul Med* 87: 226-234.
285. Al-Jedai AH, Balhareth SS, Algain RA (2012) Assessment of foetal risk associated with 93 non-US-FDA approved medications during pregnancy. *Saudi Pharm J* 20: 287-299.
286. Słopeń R, Milewska E, Rynio P, Męczekalski B (2018) Use of oral contraceptives for management of acne vulgaris and hirsutism in women of reproductive and late reproductive age. *Prz Menopauzalny* 17: 1-4.
287. Marson JW, Baldwin HE (2019) An Overview of Acne Therapy, Part 1: Topical therapy, Oral Antibiotics, Laser and Light Therapy, and Dietary Interventions. *Dermatol Clin* 37: 183-193.
288. Wiznia LE, Stevenson ML, Nagler AR (2017) Laser treatments of active acne. *Lasers Med Sci* 32: 1647-1658.
289. Kang A, Lyons A, Herrmann J, Moy R (2019) Treatment of Moderate-to-severe Facial Acne Vulgaris with Solid-state Fractional 589/1,319-nm Laser. *J Clin Aesthet Dermatol* 12: 28-31.
290. Chen S, Wang Y, Ren J, Yue B, Lai G, et al. (2019) Efficacy and safety of intense pulsed light in the treatment of inflammatory acne vulgaris with a novel filter. *J Cosmet Laser Ther* 25: 1-5.
291. Niwa AB, Mello AP, Torezan LA, Osório N (2009) Fractional photo thermolysis for the treatment of hypertrophic scars: clinical experience of eight cases. *Dermatol Surg* 35: 773-777.
292. Khatri KA, Mahoney DL, McCartney MJ (2011) Laser scar revision: A review. *J Cosmet Laser Ther* 13: 54-62.
293. Nouri K, Rivas MP, Stevens M, Ballard CJ, Singer L, et al. (2009) Comparison of the effectiveness of the pulsed dye laser 585 nm versus 595 nm in the treatment of new surgical scars. *Lasers Med Sci* 24: 801-810.
294. Keaney TC, Tanzi E, Alster T (2016) Comparison of 532 nm Potassium Titanyl Phosphate Laser and 595 nm Pulsed Dye Laser in the Treatment of Erythematous Surgical Scars: A Randomized, Controlled, Open-Label Study. *Dermatol Surg* 42: 70-76.
295. Tierney E, Mahmoud BH, Srivastava D, Ozog D, Kouba DJ (2009) Treatment of surgical scars with non-ablative fractional laser versus pulsed dye laser: a randomized controlled trial. *Dermatol Surg* 35: 1172-1180.
296. Tierney EP, Eisen RF, Hanke CW (2011) Fractionated CO2 laser skin rejuvenation. *Dermatol Ther* 24: 41-53.
297. Alexiades-Armenakas MR, Dover JS, Arndt KA (2008) The spectrum of laser skin resurfacing: non-ablative, fractional, and ablative laser resurfacing. *J Am Acad Dermatol* 58: 719-37.
298. You HJ, Kim DW, Yoon ES, Park SH (2016) Comparison of four different lasers for acne scars: Resurfacing and fractional lasers. *J Plast Reconstr Aesthet Surg* 69: e87-95.
299. Alexiades M (2017) Laser and light-based treatments of acne and acne scarring. *Clin Dermatol* 35: 183-189.
300. Ebede TL, Arch EL, Berson D (2009) Hormonal treatment of acne in women. *J Clin Aesthet Dermatol* 2: 16-22.
301. Freiman A, Barankin B (2012) Five things to know about...: acne. *CMAJ*. 184: 1497.
302. Harris S (2018) Can dietary changes help acne? *Medical NewsToday*.
303. Jaisamrarn U, Santibenchakul S (2018) A comparison of combined oral contraceptives containing chlormadinone acetate versus drospirenone for the treatment of acne and dysmenorrhea: a randomized trial. *Contracept Reprod Med* 3: 5.